




## ■ REVIEW ARTICLE

# Dysfunction of the tendon of tibialis posterior



H.-J. Trnka

From the  
Orthopaedic  
Hospital Gersthof,  
Vienna, Austria

An acquired flat-foot deformity caused by dysfunction of the tendon of tibialis posterior is common but often missed. Rupture of the tendon was first described in 1953.<sup>1</sup> In 1969 Kettelkamp and Alexander<sup>2</sup> published results of surgical exploration. They concluded that satisfactory results could not be obtained in cases of delayed repair and loss of tendon substance. There were no further reports of the condition for another ten years.<sup>3,4</sup> Since then, methods of treatment have evolved and the pathology and function of the tendon have been extensively investigated.

### Anatomy and pathophysiology

Tibialis posterior arises from the interosseous membrane and the proximal adjacent surfaces of the tibia and fibula. It is part of the deep posterior compartment of the calf. The tendon forms in the distal third of the calf and passes behind the medial malleolus where it changes direction. To prevent dislocation, the tendon is encased in a sheath beneath the flexor retinaculum. Distally, the retinaculum blends with the sheath of the tendon and the superficial deltoid ligament. The tendon of tibialis posterior does not have a mesotendon. There is an area of relative hypovascularity immediately distal to the medial malleolus, which may contribute to the development of degenerative changes and consequent rupture. The anterior slip of the tendon inserts primarily into the tuberosity of the navicular, the inferior capsule of the medial naviculocuneiform joint and the inferior surface of the medial cuneiform. A second slip extends to the plantar surfaces of the cuneiforms and the bases of the second, third and fourth metatarsals.

Since it lies posterior to the axis of the ankle and medial to the axis of the subtalar joint, its function is to plantar flex the ankle and invert the foot and therefore to invert the midfoot and elevate the medial longitudinal arch.

During normal gait, contraction of tibialis posterior causes subtalar inversion, and locking of the calcaneocuboid and talonavicular

joints (the transverse tarsal joint). Without activity of tibialis posterior there is no stability at the midtarsal joint and the forward propulsive force of the complex of gastrosoleus acts at the midfoot instead of at the metatarsal heads. This creates excessive midfoot stress which leads to collapse of the medial longitudinal arch, eversion of the subtalar joint, valgus of the heel, and abduction of the foot at the talonavicular joint.

The relative strength of tibialis posterior which is more than twice that of peroneus brevis, its primary antagonist, is due to its large cross-sectional area. Because of its short excursion, elongation of the tendon by only one centimetre makes it ineffective as the primary restraint to the longitudinal arch.<sup>5</sup>

The blood supply of the tendon may be divided into the proximal and distal areas. The proximal area is supplied by branches of the posterior tibial artery and the distal, which is at the bone-tendon interface, by branches of the posterior tibial and dorsalis pedis arteries. This pattern of blood supply produces a zone of hypovascularity of 14 mm, beginning 4 cm proximal to the insertion of the tendon.<sup>6</sup>

### Aetiology

The aetiology of dysfunction of the tendon of tibialis posterior ranges from inflammatory synovitis to degenerative rupture and, occasionally, to acute trauma. Myerson, Solomon and Shereff<sup>7</sup> identified two groups of patients with dysfunction of the tendon. In the first group are patients with a mean age of 30 years who may present with some form of systemic inflammatory disease. The second group is older with a mean age of 55 years, and dysfunction is caused by chronic overuse. It has been noted that there is an increased incidence of rupture of the tendon in obese middle-aged women and in patients with hypertension or diabetes. Acute trauma is rarely the cause of rupture. Jahss<sup>4</sup> and Holmes and Mann<sup>8</sup> reported that injection of steroids or the oral intake of corticosteroids is also associated with rupture.

■ H.-J. Trnka, MD, PhD,  
Consultant Orthopaedic  
Surgeon  
Orthopaedic Hospital  
Gersthof, Wilemangasse  
28, 1180 Vienna, Austria.

Printed with permission of  
EFORT. The original version  
of this article appears in  
*European Instructional  
Course Lectures* Vol. 6, 2003.

©2004 British Editorial  
Society of Bone and  
Joint Surgery  
doi:10.1302/0301-620X.86B7.  
15084 \$2.00  
*J Bone Joint Surg [Br]*  
2004;86-B:939-46.

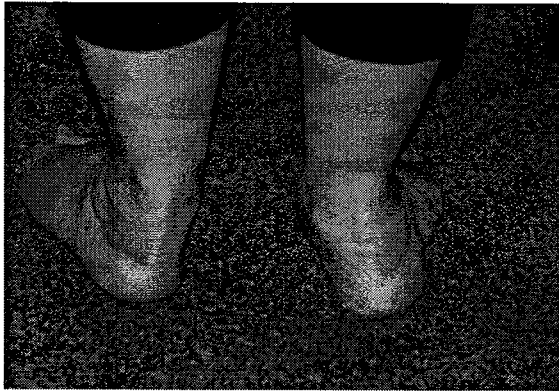

Fig. 1

Photograph showing the 'too many toes sign'. From behind, more lesser toes can be visualised on the affected left side with hindfoot valgus and forefoot abduction.

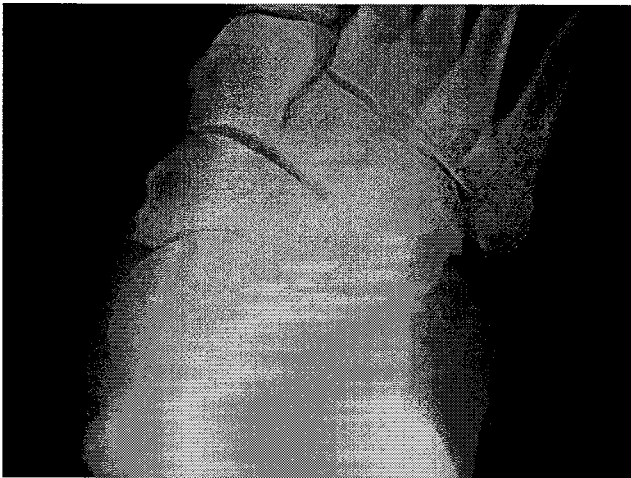


Fig. 2

A standing anteroposterior radiograph showing increased talonavicular uncoverage associated with peritalar lateral subluxation.

It is most likely, however, that rupture is caused by an intrinsic abnormality or a failure of the tendon. Its acute angulation as it passes posterior to the medial malleolus and the zone of hypovascularity distal to the medial malleolus contribute to the pathology. The hypovascular zone is the area in which most degenerative changes and ruptures are found.

### Diagnosis

**History.** In the early stages of dysfunction patients describe discomfort medially along the course of the tendon as well as fatigue and aching on the plantar medial aspect of the foot and ankle. In the presence of tenosynovitis, swelling is common. As the deformity progresses they report that the shape of the foot changes. The pain is no longer on the

medial but on the lateral side where the fibula impinges against the calcaneum. Patients find standing on their toes difficult and painful and notice a gradual collapse of the longitudinal arch with the development of valgus of the hindfoot. A typical observation is abnormal wear of the medial side of the shoes. Walking increases the pain and participation in sports becomes difficult or impossible.<sup>9,10</sup> **Clinical examination.** Careful clinical examination is essential. Both feet should be examined with the patient standing with the entire limb visible to assess overall alignment. Genu valgum may accentuate the flat foot.

The foot should be inspected from above as well as from behind the patient. Valgus angulation of the hindfoot and abduction of the forefoot are best appreciated if the foot is seen from behind. Johnson described the so-called 'too many toes sign'; with more advanced deformity the lesser toes become more visible if the foot is viewed from behind (Fig. 1). Function of the hindfoot can best be assessed by the double-limb heel rise. The patient is asked to attempt to rise on to the ball of one foot while the other is lifted off the floor. The affected hindfoot will stay in valgus while the normal foot is brought into inversion by the functioning tibialis posterior tendon. Furthermore, the patient will be unable to perform a single heel rise with the affected foot.<sup>9</sup>

Hintermann and Gachter<sup>11</sup> described the first metatarsal rise sign. The patient stands, fully loading both feet. The shin of the affected side is taken with one hand and externally rotated. By doing this the heel is passively brought into a varus position because of the mechanical coupling between the tibia and calcaneum.<sup>12</sup> The head of the first metatarsal remains on the ground in normal function of the tendon but is lifted in dysfunction.

With the patient seated, the strength of the tendon is evaluated by asking the patient to plantar flex and invert the foot against resistance. During the test, the examiner holds the hindfoot in plantar flexion and eversion and the forefoot in abduction. This eliminates the synergistic action of tibialis anterior and allows the strength of the tendon to be assessed more accurately.<sup>10,13</sup> The integrity of the tendon and the site of maximum tenderness should also be assessed. The subtalar and ankle joints are then assessed for mobility. Most important is assessment of the tendo Achillis for contracture. With increased valgus angulation of the heel, the tendo Achillis assumes a position lateral to the axis of the subtalar joint and the gastrocnemius group shortens.

The position of the forefoot is assessed with the heel in neutral. This is a critical part of the examination. As the hindfoot deformity increases, the forefoot and midfoot compensate by progressive supination. A fixed deformity may occur. It is important to identify any fixed supination deformity of the forefoot because it will affect the method of treatment.<sup>9</sup>

### Methods of examination

**Radiography.** Radiographic studies are not required to diagnose dysfunction of the tendon of tibialis posterior, but they

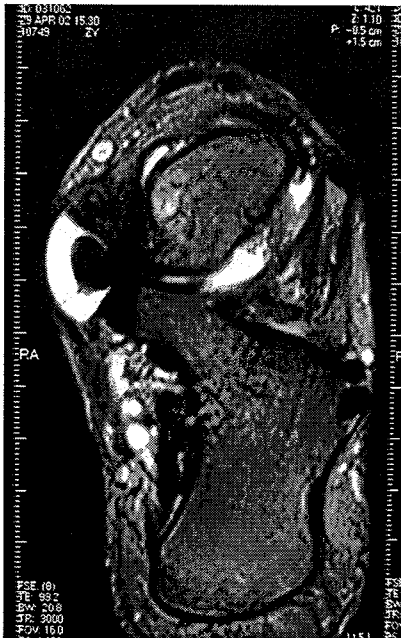


Fig. 3

MR scan showing stage-I tenosynovitis of the tendon of tibialis posterior. There is massive synovitis around the tendon.

are important for staging the deformity and selecting treatment. Radiography should include anteroposterior (AP) and lateral weight-bearing radiographs of both feet and mortise views of both ankles. As the clinical deformity progresses the AP view shows lateral subluxation of the talonavicular joint (uncoverage) as the navicular slides laterally on the talar head<sup>14</sup> (Fig. 2). The lateral radiograph shows a decrease in the talometatarsal angle, the normal value of which is 0° to 10°, and in the distance of the medial cuneiform from the floor (normal distance, 15 to 25 mm) compared with the contralateral side.<sup>9,10</sup>

**Tenography.** This has been used to assess the integrity of the tendon, but the results were disappointing and the procedure involved considerable discomfort for the patients.

**MRI.** This is the best method for assessing a ruptured tendon. The size, shape, and internal signal of the tendon are best seen on axial sections. The tendon should be imaged from above the medial malleolus to its insertion on the navicular. Tenosynovitis (Fig. 3) and splits, ruptures, and degeneration can be diagnosed.<sup>15-17</sup> Conti et al<sup>15</sup> developed a classification of tears of the tendon based on the MRI findings. In type-I tears, one or two fine longitudinal splits in the tendon are seen. Type-II tears are characterised by wider longitudinal splits and intramural degeneration, which are seen as grey areas in the tendon. The tendon may show a variable diameter on selected cuts. Type-III tears have more diffuse swelling and uniform degeneration. A few strands may remain, but most of the tendon is replaced by scar tissue or a complete gap is visible.

Rosenberg<sup>17</sup> reported that MRI is the best method for imaging the tendon because of its multiplanar imaging ability and soft-tissue contrast resolution. He found that MRI had a sensitivity of 95%, a specificity of 100% and accuracy of 96% in diagnosing disorders of the tendon.

**Ultrasound.** This is now recognised as a cost-effective and accurate method for evaluating disorders of the tendon. Its normal posterior diameter is between 4 and 6 mm and it appears hyperechoic.<sup>18</sup> Tenosynovitis presents with a large amount of fluid surrounding the tendon. A hypoechoic rim visible on the longitudinal sonogram and a target sign on the transverse sonogram are classic signs of synovitis of the tendon. Ultrasound may reveal a swollen tendon, an irregular contour, longitudinal splits, heterogeneous echogenicity, and an empty tibial groove at the level of the medial malleolus in cases of rupture. The sensitivity and specificity are similar to those of MRI.<sup>18</sup> Chen and Liang<sup>19</sup> suggested that ultrasound should be used as a routine screening modality in order to enhance the ability to diagnose stage-I dysfunction of the tendon.

### Classification

There is a continuum of dysfunction of the tendon of tibialis posterior ranging from tenosynovitis to fixed deformity.<sup>9</sup> In 1989 Johnson and Strom<sup>20</sup> described three clinical stages of dysfunction. Myerson et al<sup>7</sup> added a fourth to describe the most severe deformity with valgus collapse of the talus within the ankle.

Stage I incorporates tenosynovitis. In this stage, the tendon is of normal length and symptoms are usually mild to moderate. Pain and swelling are present on the medial aspect of the foot. Mild weakness and minimal deformity are present. In stage II there is elongation or tearing of the tendon. The limb is weak and the patient is unable to stand on tiptoe on the affected side. There is secondary deformity as the midfoot pronates and the forefoot abducts at the transverse tarsal joint. The subtalar joint remains mobile. Stage III is characterised by a more severe deformity and a fixed hindfoot and in stage IV there is a valgus deformity of the talus with early degenerative changes of the ankle.

### Treatment

**Non-operative.** This should be attempted for most symptomatic patients who have dysfunction of the tendon unless there is a significant structural deformity. It includes rest, anti-inflammatory medication and immobilisation. The local infiltration of steroids around the tendon is not indicated in any type of dysfunction.<sup>8,20</sup>

The primary treatment for acute tenosynovitis is immobilisation either in a below-knee cast or in a boot for six to eight weeks. This should prevent overuse and subsequent rupture of the tendon. A removable stirrup brace is not sufficient since it does not limit movement in the sagittal plane.<sup>9</sup> The patient is allowed to walk while wearing the cast or boot if it does not cause pain.<sup>21</sup>

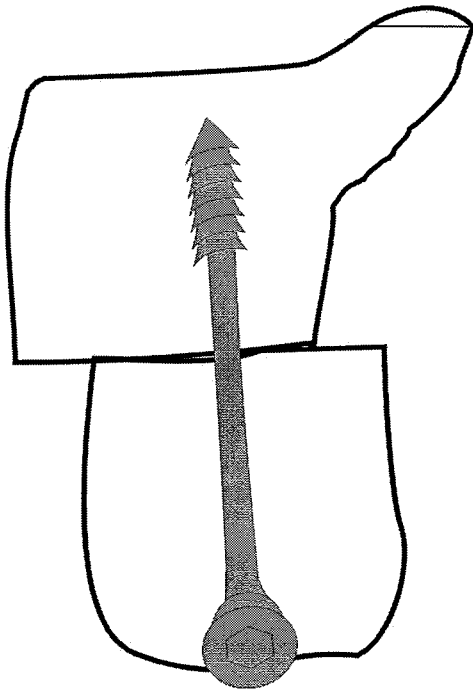


Fig. 4

Diagram of a medial displacement of a calcaneal osteotomy. The posterior fragment is displaced 1 cm medially.

Medication should be used in combination with immobilisation. Non-steroidal anti-inflammatory agents in continuous doses for two weeks are most effective. This regime allows adequate blood levels to be reached, thereby actively eliminating inflammation.

Several regimes of physiotherapy may be tried in patients using a removable boot. Iontophoresis, in which dexamethasone is introduced into the deep soft tissue by an electric current, has an effective anti-inflammatory effect and no documented risk of rupture of the tendon. Cryotherapy and massage with ice can be used as part of a home programme.

Orthoses can be made from a variety of materials and classified according to their intrinsic rigidity as either rigid, semirigid, or soft. For stage-I or mild stage-II dysfunction, a semirigid, total-contact insert in a wide counter-type shoe is indicated. Its primary function is to provide support for the arch and to correct the flexible component of the deformity.<sup>21</sup> Semirigid orthotics are commonly made of ovalcork or leather. For patients with a plantar prominence, a neoprene rubber-top cover may be added to avoid the development of a plantar keratosis. The orthosis is customised by strengthening along both the medial hindfoot and forefoot. Often modifications of shoes are necessary to accommodate a foot which is deformed.

Modifications to footwear are indicated for patients with severe deformity of the hindfoot and pes planus in which the medial arch is collapsed. In addition to protection of the

soft tissue surrounding the deformity, the shoe should provide adequate space for the orthosis and the malaligned foot. The most appropriate footwear is a shoe with extra depth.

The UCBL orthosis, named from the University of California at Berkeley Laboratory, is made of rigid materials and is used to stabilise the hindfoot of a mobile foot in neutral position. It is primarily indicated in stage-II dysfunction in which the hindfoot remains mobile and is thus passively correctable. It limits forefoot abduction and controls hindfoot valgus and midfoot collapse by placing a medially directed force on the lateral shaft of the fifth metatarsal, a medially directed force on the lateral side of the calcaneum, and a laterosuperiorly directed force at the sustentaculum tali.

The short, articulated ankle-foot orthosis is another option for stage-II dysfunction. It is designed to control and restrict subtalar movement. The anterior shell also helps to control tibial rotation forces about the subtalar joint.

Ankle-foot orthoses may be either articulated or rigid. The rigid type is indicated in patients with stage-III deformity and pain secondary to subfibular impingement and the articulated type for the rare patient with an asymptomatic stage-III deformity.

#### Operative

**Synovectomy.** For isolated tenosynovitis with persistent symptoms refractory to conservative management, a synovectomy can be performed. The tendon sheath is exposed from the musculotendinous junction to its navicular insertion. When the sheath is entered, copious, thick clear and yellow-tinged synovial fluid is released. The synovectomy is done by sharp dissection, completely removing all the inflamed synovium, while preserving the blood supply to the tendon.

Postoperative management includes immobilisation for three weeks followed by wearing a boot with controlled ankle movement for another three weeks and physiotherapy. Six weeks after operation a stirrup ankle brace may be worn.<sup>22</sup>

**Transfer of flexor digitorum longus and medial displacement osteotomy.** A calcaneal osteotomy may be used to treat valgus angulation of the heel by moving the calcaneum medially and thus altering the mechanical axis of the lower limb.<sup>9,23</sup> The medial displacement of the calcaneum redirects the pull of the gastrocnemius muscle group slightly medial to the axis of the subtalar joint, increasing its varus pull on the hindfoot. The osteotomy recommended by Myerson et al<sup>24</sup> and Saxby and Myerson<sup>25</sup> is a simple medial displacement osteotomy of the posterior part of the calcaneum. This procedure is indicated in combination with synovectomy for patients who have advanced stage-I deformity and in conjunction with transfer of the tendon of flexor digitorum longus for those who have stage-II deformity.

The patient is placed in the lateral decubitus position. The incision is made 1.5 finger widths behind the lateral

malleolus parallel to the peroneal tendons and posterior to the sural nerve. It extends from the superior border of the calcaneal tuberosity to the inferior border of the calcaneum. After deepening of the incision and retraction of the soft tissues, the periosteum is reflected. With an oscillating saw, a transverse osteotomy in the calcaneum is made in line with the incision. The cut is made at a right angle to the lateral border of the calcaneum and is inclined posteriorly at an angle of 45° to the plane of the sole of the foot. A laminar spreader is inserted into the site of the osteotomy, and the medial soft-tissue attachments on to the calcaneum are released by spreading the device open. The posterior fragment is then translated 1 cm medially and secured by a cannulated cancellous lag screw (Fig. 4).

**Transfer of the flexor tendon.** This is performed for stage-I or stage-II dysfunction in association with weakness, valgus angulation of the hindfoot, pain in the medial part of the foot and a mobile transverse tarsal and subtalar joint. If there is not adequate movement in the subtalar and transverse tarsal joints, a tendon transfer will fail. The position of the forefoot is another important consideration because more than 12° to 15° of fixed forefoot varus negates the tendon transfer. If the patient does not meet the criteria for a tendon transfer, an arthrodesis is indicated.<sup>9</sup>

The decision as to which tendon is used is based on the axes of the ankle and subtalar joints, the relationship of the tendon to the axes, the various muscle strengths, and the phasic activity of the particular muscle/tendon unit. Silver et al<sup>5</sup> described the relative muscle strengths of the tendons around the ankle. They found that the tendon of tibialis posterior has a relative strength of 6.4 compared with 1.8 for the tendon of flexor digitorum longus (FDL). Although transfer of FDL would have the same distance from the axis of rotation as the tendon of tibialis posterior, FDL has only 30% of the strength of the latter. Because of this weakness, transfer of FDL is usually combined with a hindfoot medialisation calcaneal osteotomy to reduce the antagonistic force.

A medial longitudinal incision is made beginning 10 cm proximal to the medial malleolus along the tendon of tibialis posterior directed distally beyond the navicular in line with the first metatarsal. The sheath of the tendon of tibialis posterior is opened, the tendon is inspected and divided 1 cm proximal to its insertion into the navicular.

The adjacent tendon of FDL is identified in its sheath. The plane of dissection should be deep to abductor hallucis and flexor digitorum brevis. Distal dissection should allow identification of both the tendons of flexor hallucis longus and FDL. The latter should be divided if possible under direct vision. It is not necessary to perform a tenodesis of flexor hallucis longus to the stump of FDL since there are multiple interconnections between the two.<sup>26</sup>

The periosteum over the navicular is then dissected and a drill hole of 4.5 to 5 mm is made in the tuberosity from the dorsal to plantar aspects. The tendon is passed through the drill hole from plantar to dorsal. Before the FDL tendon is

sutured, the spring ligament and the talonavicular capsule should be inspected and if necessary a vertical ellipse should be removed and the shortened capsule closed. To avoid overstretching FDL, the tension in its tendon is set halfway between maximum tension and complete relaxation.<sup>13,27,28</sup>

Chronic rupture of the tendon of tibialis posterior may be associated with atrophy and fibrosis of the muscle. If tibialis posterior is healthy, the tendon should be sutured to the tendon of FDL at the level of the medial malleolus. When the proximal stump of the tendon is pulled in a distal direction, its normal excursion is 1 cm. If there is no excursion of the musculotendinous unit, the muscle is either scarred or fibrotic, and a tenodesis to the tendon of FDL should not be performed. At the completion of the reconstruction, the foot should rest in a position of slight equinovarus.

No weight-bearing is allowed for two weeks after which partial weight-bearing is permitted using either a below-knee cast or a hinged range-of-movement walker boot. After full walking for six to eight weeks the use of a stirrup ankle brace and physiotherapy to strengthen the muscle are advocated.

Mann and Thompson<sup>29</sup> presented the outcome of transfer of the tendon of FDL in 17 patients with excellent results in 12, good in one, fair in three and poor in one. All patients had good relief from pain and were able to return to their previous level of activity. In 1996 Myerson and Corrigan<sup>13</sup> reported their results in 32 patients. Thirty were satisfied and the AOFAS hindfoot score improved from 48 before operation to 84 at follow-up. These results were also confirmed by Wacker, Hennessy and Saxby,<sup>30</sup> who reviewed 44 patients with stage-II deformity treated by transfer of FDL and calcaneal osteotomy. In 43 the outcome was rated as excellent or good for pain and function and in 36 for alignment.

**Lengthening of the lateral column.** As the foot assumes a pes planovalgus deformity, the lateral column becomes relatively shortened with respect to the medial column.<sup>20</sup> Evans<sup>31</sup> originally described removal of a wedge from the calcaneocuboid joint to abduct the forefoot, resulting in the development of a flat-foot deformity. He then developed a procedure using an opening wedge osteotomy 1.5 mm proximally for correction of a flat foot and calcaneovalgus. Lengthening of the lateral column restored the medial longitudinal arch.

There are two techniques for lengthening the lateral column, the 'classic' Evans method which is performed 1.5 cm proximal to the calcaneocuboid joint, and the calcaneocuboid joint distraction arthrodesis. For the classic Evans procedure a transverse incision of 4 cm is made over the lateral aspect of the anterior calcaneal tuberosity. The sural nerve and the calcaneocuboid joint are identified. At 1.5 cm proximal to the calcaneocuboid joint the calcaneum is exposed by two Homann retractors. With an oscillating saw the osteotomy is performed parallel to the calcaneocuboid joint, taking care to preserve the medial cortex.

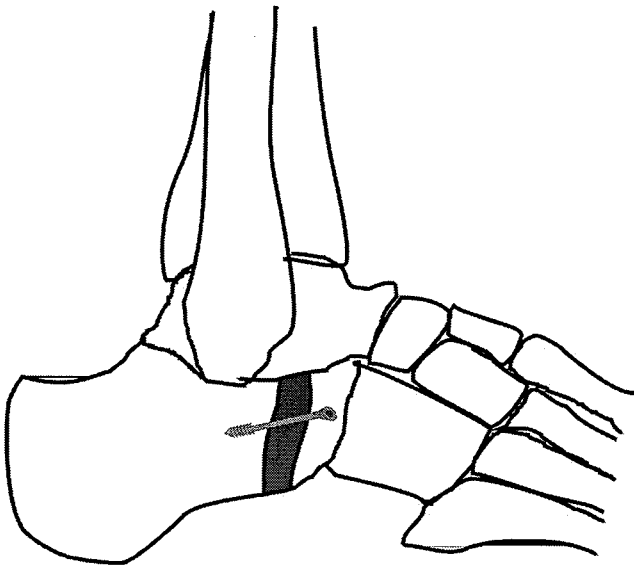


Fig. 5

Diagram of the Evans procedure.

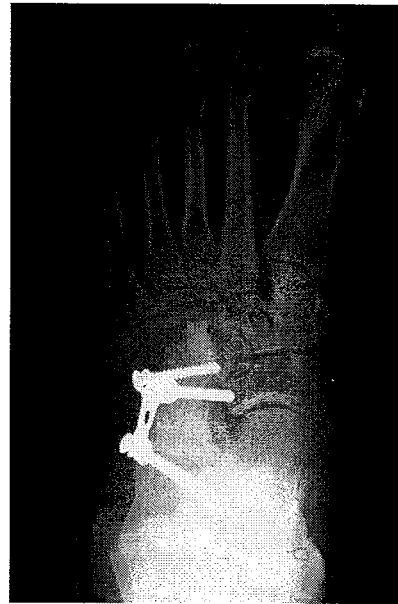


Fig. 6

Anteroposterior radiograph of a calcaneocuboid distraction fusion with H-plate fixation.

Using a laminar spreader, the osteotomy is distracted. Depending on the desired lengthening a bone graft either taken from the iliac crest or from a femoral head allograft is inserted until it is flush with the lateral surface of the calcaneum. The graft is fixed with a pin or a 3.5 to 4 mm screw. Care is taken not to penetrate the calcaneocuboid joint (Fig. 5).

For the calcaneocuboid distraction arthrodesis a transverse incision is made over the calcaneocuboid joint. Extensor digitorum brevis is split and the calcaneocuboid joint is exposed using Homann retractors. After removing the articular surface, a bone graft either taken from the iliac crest or from a femoral head allograft is inserted. The arthrodesis is either fixed by crossed cortical lag screws or an AO H-plate (Fig. 6).

**Subtalar fusion.** Isolated subtalar fusion is indicated only when the subtalar joint has a fixed deformity and the transverse tarsal joint remains mobile and free from pain.<sup>9,32,33</sup> The patient is placed in a lateral decubitus position. A straight lateral incision is made over extensor digitorum brevis (EDB) from the anterior aspect of the distal fibula to the cuboid, in line with the fourth ray. EDB is elevated to expose the sinus tarsi. The soft tissues, including fat and capsular tissue, are removed to expose the subtalar joint. Next, a laminar spreader is used to improve visualisation of the subtalar joint. Using an osteotome cartilage is removed and the subchondral bone of the posterior calcaneal facet, the inferior articular surface of the talus, and the middle and anterior facets of the subtalar joint, are exposed. The subtalar joint is reduced. A partially threaded cannulated screw (with the head away from the weight-bearing sur-

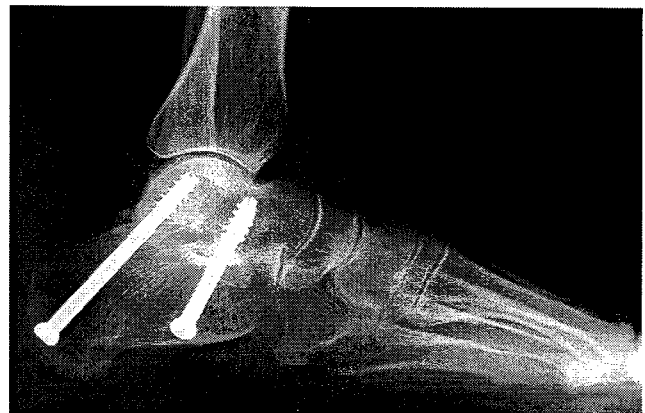

Fig. 7

Lateral radiograph of subtalar fusion.

face) is passed from the calcaneum to the talus under fluoroscopic guidance. Weight-bearing is restricted for six weeks after which it is started as tolerated<sup>34</sup> (Fig. 7).

The concept of limited fusion is to allow correction of the deformity, with maximal preservation of movement in the surrounding joints. Mann, Beaman and Horton<sup>35</sup> found that patients retained 60% of transverse tarsal movement, 70% of dorsiflexion and 90% of plantar flexion of the ankle. Various reports show satisfactory results after subtalar fusion in the treatment of dysfunction of the tibialis posterior tendon with low rates of complications.<sup>35-37</sup> Kitaoka and Patzer<sup>36</sup>

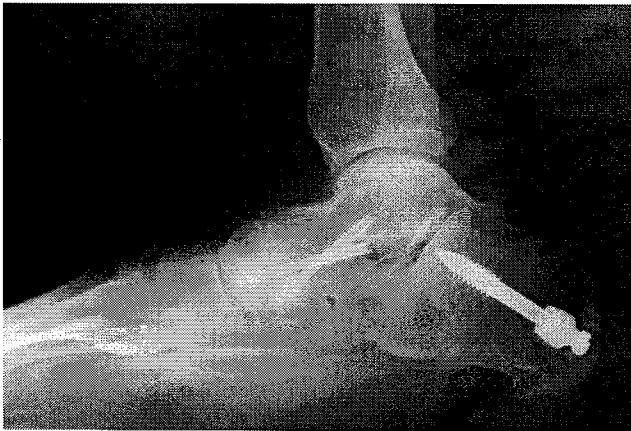

Fig. 8

Lateral radiograph of talonavicular fusion with a medial displacement calcaneal osteotomy.

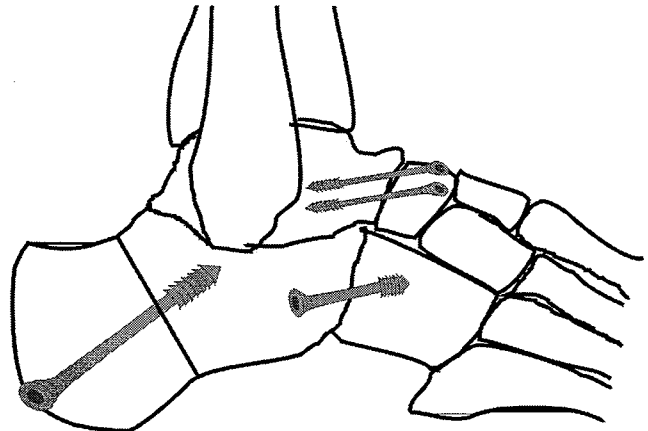


Fig. 9

Diagram of a triple fusion.

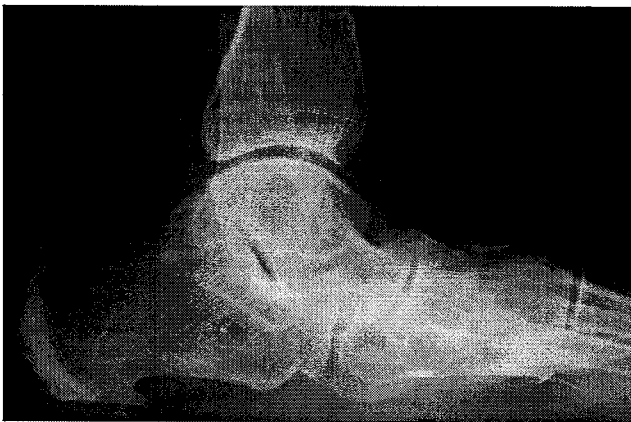


Fig. 10

Preoperative lateral radiograph of stage-III dysfunction of the tendon of tibialis posterior.

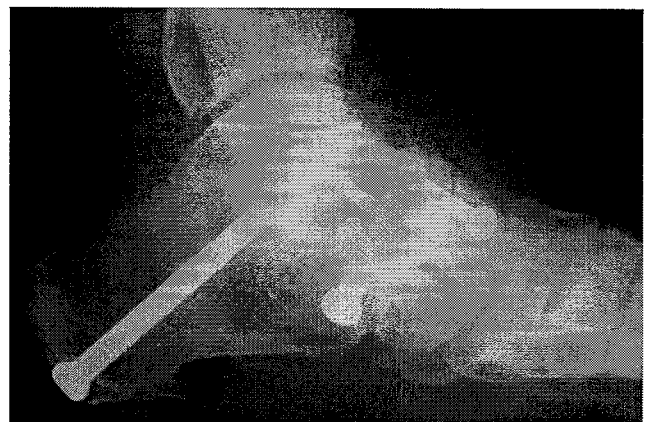


Fig. 11

Lateral radiograph of triple fusion for stage-III dysfunction.

reported the results of subtalar fusion in 21 patients with a follow-up for three years. The rate of union was 100% and with significant improvement of all radiographic measurements. Functionally, subtalar fusion causes minimal alterations of gait on flat surfaces and can lead to the long-term maintenance of alignment of the hindfoot.

**Fusion of the talonavicular joint.** Isolated fusion of the talonavicular joint has been shown to correct the components of flat-foot deformity in the clinical setting and in cadaver models.<sup>38,39</sup> The joint is identified and exposed through a longitudinal dorsomedial incision just medial to the tendon of tibialis anterior. Aggressive stripping of the talar neck and navicular should be avoided in order to preserve the blood supply to the area. Using an osteotome, cartilage and subchondral bone are removed. In order to facilitate exposure of the lateral aspect of the joint, a laminar spreader is

inserted into the joint. Care is taken to maintain the normal contour of the navicular and the talus to facilitate reduction of the joint and to maximise apposition of the bone surfaces. Once the proper position has been obtained, lag screws or staples are used to secure the fusion. As the navicular is moved medially, there is a tendency for the foot to supinate as a result of forefoot varus which is often present in severe planovalgus deformities. Forefoot varus must be corrected by rotating the arthrodesis (Fig. 8). After operation, patients are immobilised in a non-weight-bearing cast for six weeks followed by a walking cast for four to six weeks.

There are no long-term follow-up studies of isolated talonavicular fusion specifically related to flat-foot deformity in the adult. Harper<sup>38</sup> reported 27 patients with a minimum follow-up of one year. Good to excellent results were

obtained in 24. Progressive adjacent arthritis of the navicula-cuneiform and subtalar joints was noted in four patients. Lateral midfoot pain was reported as the most common cause of dissatisfaction. Mann and Beaman<sup>40</sup> suggested double fusion with inclusion of the calcaneocuboid joint. **Triple arthrodesis.** A triple arthrodesis is indicated for a fixed hindfoot deformity with associated pain in the lateral aspect of the foot. The goals are to realign the hindfoot and to establish a plantigrade weight-bearing surface. The patient is first placed in the lateral supine position. A longitudinal incision is made overlying the sinus tarsi. After elevating EDB the calcaneocuboid and subtalar joints are exposed. Using a chisel, the cartilage of both is removed. The talonavicular joint is now approached, and using an osteotome, cartilage and subchondral bone are removed. Some surgeons advocate fixing the talonavicular joint first while others believe that the subtalar joint should be stabilised first. Myerson<sup>9</sup> suggests that realigning the medial column at the talonavicular joint is the key to aligning the rest of the foot (Figs 9 to 11).

Pell, Myerson and Schon<sup>41</sup> reported the outcome after primary triple arthrodesis in 111 patients (132 feet), 63 of whom had dysfunction of the tendon of tibialis posterior. At a mean follow-up of 5.7 years they reported high rates of satisfaction and improvement in the post-operative modified AOFAS score. Fortin and Walling<sup>42</sup> reported results in 25 patients with 32 fused hindfeet. Twenty-two rated their surgery as a success. There was one case of nonunion and two of varus malunion which required revision surgery.

There are multiple non-operative and operative options for the treatment of acquired flat foot secondary to dysfunction of the tendon of tibialis posterior. It is important to establish the correct diagnosis and staging in order to choose the best method of treatment.

## References

1. Key JA. Partial rupture of the tendon of the posterior tibial muscle. *J Bone Joint Surg [Am]* 1953;35-A:1006-8.
2. Kettelkamp DB, Alexander HH. Spontaneous rupture of the posterior tibial tendon. *J Bone Joint Surg [Am]* 1969;51-A:759-64.
3. Mann RA. Acquired flatfoot in adults. *Clin Orthop* 1983;181:46-51.
4. Jahss M. Spontaneous rupture of the tibialis posterior tendon: clinical findings, tenographic studies, and a new technique of repair. *Foot Ankle* 1982;3:158-66.
5. Silver RL, Garza J, Rang M. The myth of muscle balance: a study of relative strengths and excursions of normal muscles about the foot and ankle. *J Bone Joint Surg [Br]* 1985;67-B:432-7.
6. Frey C, Shereff M, Greenidge N. Vascularity of the posterior tibial tendon. *J Bone Joint Surg [Am]* 1990;72-A:884-8.
7. Myerson M, Solomon G, Shereff M. Posterior tibial tendon dysfunction: its association with seronegative inflammatory disease. *Foot Ankle* 1989;9:219-25.
8. Holmes GB Jr, Mann RA. Possible epidemiological factors associated with rupture of the posterior tibial tendon. *Foot Ankle* 1992;13:70-9.
9. Myerson MS. Adult acquired flatfoot deformity. *J Bone Joint Surg [Am]* 1996;78-A:780-92.
10. Slovenkai MP. Clinical and radiographic evaluation. *Foot Ankle Clin* 1997;2:241-60.
11. Hintermann B, Gachter A. The first metatarsal rise sign: a simple, sensitive sign of tibialis posterior tendon dysfunction. *Foot Ankle Int* 1996;17:236-41.
12. Hintermann B, Nigg BM, Sommer C. Foot movement and tendon excursion: an in vitro study. *Foot Ankle Int* 1994;15:386-95.
13. Myerson MS, Corrigan J. Treatment of posterior tibial tendon dysfunction with flexor digitorum longus tendon transfer and calcaneal osteotomy. *Orthopedics* 1996;19:383-8.
14. Johnson KA. Tibialis posterior tendon rupture. *Clin Orthop* 1983;177:140-7.
15. Conti S, Michelson J, Jahss M. Clinical significance of magnetic resonance imaging in preoperative planning for reconstruction of posterior tibial tendon ruptures. *Foot Ankle* 1992;13:208-14.
16. Resenberg ZS, Cheung Y, Jahss MH, et al. Rupture of posterior tibial tendon: CT and MR imaging with surgical correlation. *Radiology* 1988;169:229-35.
17. Resenberg ZS. Chronic rupture of the posterior tibial tendon. *Magn Reson Imaging Clin N Am* 1994;2:79-87.
18. Miller SD, Van Holsbeeck M, Boruta PM, Wu KK, Katcherian DA. Ultrasound in the diagnosis of posterior tibial tendon pathology. *Foot Ankle Int* 1996;17:555-8.
19. Chen YJ, Liang SC. Diagnostic efficacy of ultrasonography in stage I posterior tibial tendon dysfunction: sonographic-surgical correlation. *J Ultrasound Med* 1997;16:417-23.
20. Johnson KA, Strom DE. Tibialis posterior tendon dysfunction. *Clin Orthop* 1989;239:196-206.
21. Sierra JJ, Rosenberg GA. Nonoperative treatment of posterior tibial tendon pathology. *Foot Ankle Clin* 1997;2:261-73.
22. Bare AA, Haddad SL. Tenosynovitis of the posterior tibial tendon. *Foot Ankle Clin* 2001;6:37-66.
23. Trnka HJ, Easley ME, Myerson MS. The role of calcaneal osteotomies for correction of adult flatfoot. *Clin Orthop* 1999;365:50-64.
24. Myerson MS, Corrigan J, Thompson F, Schon LC. Tendon transfer combined with calcaneal osteotomy for treatment of posterior tibial tendon insufficiency: a radiological investigation. *Foot Ankle Int* 1995;16:712-18.
25. Saxby T, Myerson MS. Calcaneus osteotomy. In: Myerson MS, ed. *Current therapy in foot and ankle surgery*. St Louis: Mosby 1993,159-62.
26. Wapner KL, Hecht PJ, Shae JR, Allardyce TJ. Anatomy of second muscular layer of the foot: considerations for tendon selection in transfer for Achilles and posterior tibial tendon reconstruction. *Foot Ankle Int* 1994;15:420-3.
27. Den Hartog BD. Flexor digitorum longus transfer with medial displacement calcaneal osteotomy: biomechanical rationale. *Foot Ankle Clin* 2001;6:67-76.
28. Guyton GP, Jeng C, Krieger LE, Mann RA. Flexor digitorum longus transfer and medial displacement calcaneal osteotomy for posterior tibial tendon dysfunction: a middle-term clinical follow-up. *Foot Ankle Int* 2001;22:627-32.
29. Mann RA, Thompson FM. Rupture of the posterior tibial tendon causing flat foot: surgical treatment. *J Bone Joint Surg [Am]* 1985;67-A:558-61.
30. Wacker JT, Hennessy MS, Saxby TS. Calcaneal osteotomy and transfer of the tendon of flexor digitorum longus for stage-II dysfunction of tibialis posterior: three- to five-year results. *J Bone Joint Surg [Br]* 2002;84-B:54-8.
31. Evans D. Calcaneo-valgus deformity. *J Bone Joint Surg [Br]* 1975;57-B:270-8.
32. Cohen BE, Johnson JE. Subtalar arthrodesis for treatment of posterior tibial tendon insufficiency. *Foot Ankle Clin* 2001;6:121-8.
33. Johnson JE, Cohen BE, DiGiovanni BF, Lamdan R. Subtalar arthrodesis with flexor digitorum longus transfer and spring ligament repair for treatment of posterior tibial tendon insufficiency. *Foot Ankle Int* 2000;21:722-9.
34. Easley ME, Trnka HJ, Schon LC, Myerson MS. Isolated subtalar arthrodesis. *J Bone Joint Surg [Am]* 2000;82-A:613-24.
35. Mann RA, Beaman DN, Horton GA. Isolated subtalar arthrodesis. *Foot Ankle Int* 1998;19:511-19.
36. Kitaoka HB, Patzer GL. Subtalar arthrodesis for posterior tibial tendon dysfunction and pes planus. *Clin Orthop* 1997;345:187-94.
37. Mangone HB, Fleming LL, Fleming SS, et al. Treatment of acquired adult planovalgus deformities with subtalar fusion. *Clin Orthop* 1997;345:106-12.
38. Harper MC. Talonavicular arthrodesis for the acquired flatfoot in the adult. *Clin Orthop* 1999;365:65-8.
39. O'Malley MJ, Deland JT, Lee KT. Selective hindfoot arthrodesis for the treatment of adult acquired flatfoot deformity: an in vitro study. *Foot Ankle Int* 1995;16:411-17.
40. Mann RA, Beaman DN. Double arthrodesis in the adult. *Clin Orthop* 1999;365:74-80.
41. Pell RF, Myerson MS, Schon LC. Clinical outcome after primary triple arthrodesis. *J Bone Joint Surg [Am]* 2000;82-A:47-57.
42. Fortin PT, Walling AK. Triple arthrodesis. *Clin Orthop* 1999;365:91-9.