

Original Research

General Short-Term Indomethacin Prophylaxis to Prevent Heterotopic Ossification in Total Hip Arthroplasty

S. Hofmann, MD*

H.-J. Trnka, MD†

H. Metzenroth, MD†

E. Frank, MD‡

P. Ritschl, MD†

M. Salzer, MD‡

A B S T R A C T

This prospective study evaluated heterotopic ossification prophylaxis with indomethacin for 14 days in 201 consecutive patients undergoing total hip arthroplasty. Ranitidine was administered concurrently to alleviate gastrointestinal side effects. None of the patients with mild gastrointestinal side effects (12%) had to suspend the prophylaxis, and no major postoperative bleeding or gastrointestinal ulcers were observed. After 12

months of follow-up, 67% of patients had no evidence of heterotopic ossification, 32% percent had grades I and 1% had grade III without clinical significance, and 0% had grade IV ossification according to Brooker's classification. These results indicate that short-term indomethacin prophylaxis is an effective, inexpensive, and easily administered alternative to single-dose radiotherapy for nearly all patients undergoing THA.

The development of heterotopic ossification following total hip arthroplasty (THA) is a well-documented complication that might interfere with patient outcome. The incidence of total heterotopic ossification ranges from 8% to 90%, and the incidence of clinically significant lesions has been reported to range from 1% to 24%.¹⁻⁸ Pain and decreased range of motion are the common limiting factors for the patient and can even cause virtual ankylosis of the hip joint.

Various efforts to prevent heterotopic ossification have been undertaken

in the past.^{9,10} Local radiation^{11,12} and anti-inflammatory medication^{6,13-17} are the two established and effective treatment modalities to prevent heterotopic ossification after THA.

Indomethacin is the most common prophylactic drug and has been thoroughly investigated regarding its efficacy.¹⁸⁻²⁷ Increased postoperative bleeding, dyspepsia, gastric ulcer, renal dysfunction, and cerebral confusion are short-term side effects, while reduced bony ingrowth in the prosthesis or nonunion of a trochanter osteotomy have been described as late-term side effects related to indomethacin.^{8,14,19,21,28}

Single-dose irradiation is the most common radiotherapeutic prophylaxis to prevent heterotopic ossification, and its efficiency has been well-documented. Nevertheless, there are logistical problems, a risk for reduced bony ingrowth, and a probable risk of sarcoma.^{11,29-33}

Because of the side effects of anti-inflammatory medication and the disadvantages of local irradiation, until recently heterotopic ossification prophylaxis was only recommended for patients at risk for heterotopic ossification.^{6,7,11,12,17,18,33-35} Since the development of heterotopic ossification cannot be reliably predicted before surgery in most cases, the indications for prophylaxis still remain unclear.⁶

This study investigated the practicality, efficiency, and side effects of general heterotopic ossification prophylaxis with indomethacin in THA.

MATERIALS AND METHODS

For a period of 6 months, 201 consecutive THA patients (143 women and 58 men) scheduled for THA were included in a prospective study. Mean patient age was 68.3 years (range: 32-97 years). Different surgical proce-

From the *Orthopedic Department, Danube Hospital, the †Orthopedic Department, Orthopedic Hospital Gersthof, and the ‡Orthopedic Department, Herz Jesu Hospital, Vienna, Austria.

Reprint requests: S. Hofmann, MD, Orthopedic Dept, Danube Hospital, Langobardenstrasse 122, 1230 Vienna, Austria.

(4%) cases had heterotopic ossification progressed one grade between the 3- and 12-month follow-up evaluations. Range of motion was not limited in any of the patients with grade I, II, or III heterotopic ossification nor did any of the patients complain of pain related to heterotopic ossification.

An avulsion of the tip of the trochanter major was observed on the immediate postoperative radiograph in 36 (18%) cases. In 12 of these patients, an apparent grade I heterotopic ossification and in 1 case an apparent grade III heterotopic ossification had developed at follow-up (Fig 2), but these cases were not counted as heterotopic ossification.

Of the 144 patients with uncemented primary THAs, 14 (10%) were lost to follow-up at the 24-month evaluation (9 had died, 2 had moved, and 3 could not be located). The average follow-up of the remaining 130 patients was 39 months (range: 24-68 months). None of these patients presented with clinical or radiographic signs for aseptic loosening of the femoral prosthetic component at the final follow-up.

DISCUSSION

The efficacy of anti-inflammatory heterotopic ossification prophylaxis is generally accepted, but there is still controversy about the duration of prophylaxis.⁶ Several authors advocate the use of anti-inflammatory drugs for a period of 3 up to 12 weeks.^{7,14-16,18,21,23,25} In recent studies, short-term prophylaxis from 7 to 14 days has shown to have a convincing ability to decrease heterotopic ossification,^{17,22,27,36} whereas administration for only 4 days could not achieve an acceptable prevention of heterotopic ossification.³⁷

Due to the side effects of anti-inflammatory medication, most of the studies to date have recommended prophylaxis only for patients at risk for heterotopic ossification.^{7,17,18,34} However, among the extensive literature dealing with heterotopic ossification after THA, no report has clearly shown how to predict which patients are at risk. Therefore, until

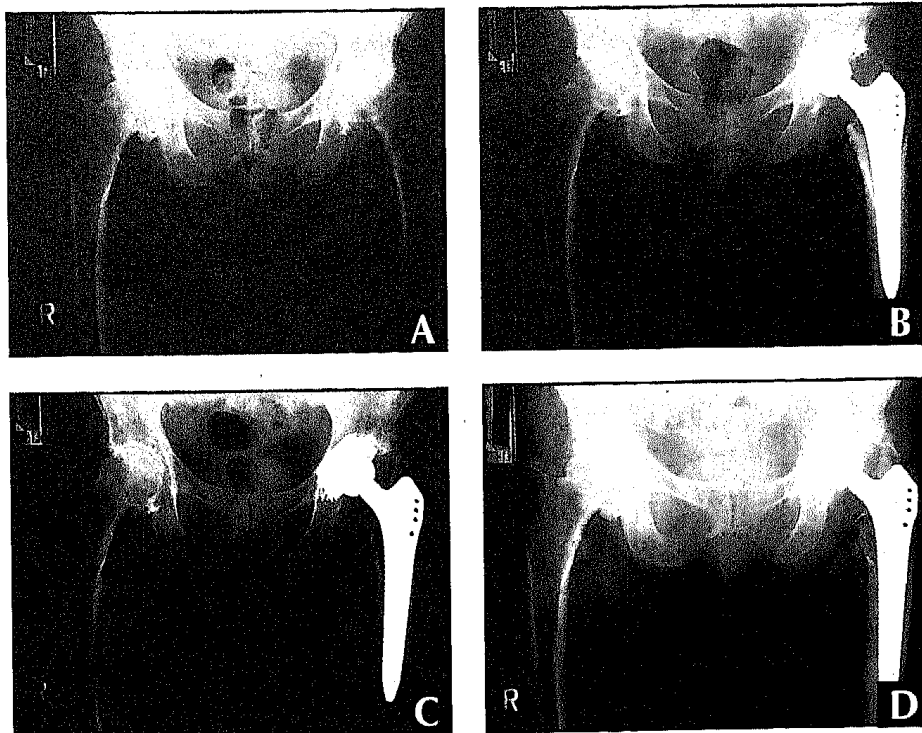


Fig 2: Preoperative radiograph (A) of a 68-year-old woman with hypertrophic osteoarthritis at low risk for heterotopic ossification. Radiograph taken 1 week postoperatively (B) demonstrates an avulsion of the greater trochanter tip. Radiograph taken 3 months postoperatively (C) shows apparent grade II heterotopic ossification while the radiograph taken 12 months postoperatively (D) shows apparent grade III heterotopic ossification with no functional impairment.

recently, many patients without evident risk factors were not treated, and some of these patients developed heterotopic ossification.⁷

Based on our own experience with anti-inflammatory heterotopic ossification prophylaxis,^{13,20,25} we have routinely used indomethacin prophylaxis since 1987 for every THA we performed. In this study, anti-inflammatory medication was proven to be an inexpensive and easily administered heterotopic ossification prophylaxis for nearly all of the patients undergoing THA. Only 1% of the patients had to be excluded preoperatively, and an additional 1% did not receive the prophylaxis due to organization failures. The reasons for interrupting the prophylaxis in 4% were not indomethacin-related, and therefore 94% of the patients successfully finished the prophylaxis.

Our results are comparable to indomethacin prophylaxis for 6 weeks or a single-dose radiotherapy.^{7,11,12,14,18,23,27,33,38} It still remains

unclear which minimum dosage of indomethacin may be sufficient, and therefore the risk of side effects might be further minimized by lower doses of anti-inflammatory drugs.⁶ Interestingly, in this study we found that an avulsion of the trochanter major might be misinterpreted as heterotopic ossification if the immediate postoperative radiographs are not analyzed carefully. The relatively high incidence of trochanter major avulsions in our series induced us to change our surgical technique.

In previous reports, indomethacin prophylaxis had to be interrupted in 20% to 30% of patients due to gastrointestinal irritation.^{14,36} The effectiveness of ranitidine or sucralfate to prevent severe gastrointestinal side effects of indomethacin prophylaxis has been proven by our group in a previous study using gastroscopic evaluation pre- and postoperatively.²⁵ In this study, using ranitidine for gastric protection, only 12% of patients experi-

TABLE
Surgical procedures

Procedure	Primary THA	Revision THA	Total THA
Uncemented	144	15	159
Hybrid	23	4	27
Cemented	8	7	15
Total	175	26	201

dures were performed (Table) using a transgluteal approach with ventral capsular excision.

A history of severe indomethacin intolerance or an active gastric ulcer were regarded as absolute contraindications, whereas severe renal, hepatic, or cardiac insufficiency were considered relative contraindications for indomethacin prophylaxis. All other patients received general short-term heterotopic ossification prophylaxis. Prophylaxis consisted of indomethacin (50 mg twice daily) for 14 days starting on the first postoperative day. Ranitidine (150 mg twice daily) also was administered to suppress gastrointestinal side effects, for 16 days starting on the day of surgery.

Heterotopic ossification risk factors, side effects of indomethacin, and reasons for interrupting the protocol were documented. High risk factors included patients with previous heterotopic ossification of the contralateral or ipsilateral hip, while low risk factors included male gender, hypertrophic or concentric osteoarthritis, and revision THA.¹²

Routine perioperative antibiotic prophylaxis up to 3 days and low-dose unfractionated heparin for at least 3 weeks were administered. Suction drainage was routinely removed after 48 hours. Patients were allowed partial weight bearing on crutches for 6 weeks. Standard radiographs (AP and frog-leg views) and clinical evaluation were performed at 1 week, 3 months, and annually thereafter.

Heterotopic ossification classification was graded according to Brooker et al⁴ using the following categories:

- grade 0—normal hip, no heterotopic bone formation,

- grade I—*islands of bone formation,*
- grade II—*heterotopic ossification from the pelvis and the proximal part of the femur, with at least 1 cm of uninvolved tissue in between,*
- grade III—*projections of heterotopic ossification from the pelvis and the proximal part of the femur, with <1 cm of uninvolved tissue in between, and*
- grade IV—*apparent ankylosis.*

Clinical assessment focused on pain and stiffness as signs for heterotopic ossification around the hip.

To evaluate the effect of indomethacin on the osteointegration of cementless femoral prostheses, the 144 patients with uncemented primary THAs were examined clinically and their radiographs analyzed for signs of aseptic loosening (subsidence, migration, and radiolucencies) of the femoral component at least 24 months after surgery.

RESULTS

No patient had an absolute contraindication such as indomethacin intolerance or active gastric ulcer, but 2 patients with relative contraindications had to be excluded from the study at the time of surgery. Eighteen (9%) patients with preexisting heterotopic ossification were considered at high risk for heterotopic ossification (Fig 1), while 87 (44%) patients had one or more heterotopic ossification low risk factor (male gender [58 patients], hypertrophic osteoarthritis [27 patients], concentric osteoarthritis [16 patients], and revision THA [26 patients]).

The two patients who did not receive no indomethacin were original-

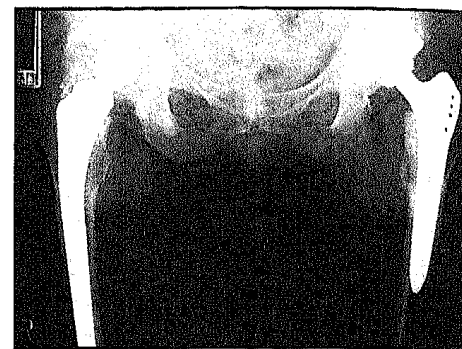


Fig 1: Radiograph of a 64-year-old woman at high risk for heterotopic ossification (grade IV heterotopic ossification in the right hip from previous surgery without indomethacin prophylaxis) demonstrates no heterotopic ossification on the left side with indomethacin prophylaxis after 12 months of follow-up.

ly included in the study, but due to organization failure at the ward, they did not receive their medication. Seven (4%) patients interrupted the protocol for non-indomethacin-related problems (4 for renal insufficiency, 1 for unclear allergy symptoms of the skin, 1 for cardiac decompensation, and 1 for diarrhea). These 9 patients were excluded from the study.

Two patients interrupted the prophylaxis for <3 days but were not excluded from the study. Twenty-four (12%) patients complained of mild side effects (gastric problems or cerebral confusion) but did not interrupt the prophylaxis. Therefore, a total of 190 (93%) patients finished the indomethacin prophylaxis successfully. No severe increased postoperative bleeding or gastrointestinal ulcers were observed during patients' hospital stay.

At 1 year postsurgery, 10 (7%) patients were lost to follow-up (4 patients had died and 6 could not be located). Out of the 180 patients available for the 1-year follow-up evaluation, 120 (67%) patients had grade 0, 55 (31%) patients had grade I, 3 (1%) patients had grade II, and 2 (1%) patients had grade III ossification according to Brooker's classification. No patient developed grade IV heterotopic ossification.

All of the heterotopic ossifications were visible at 3 month, and in only 8

enced mild gastrointestinal side effects. After explaining the necessity of the prophylaxis to the patients, these side effects were tolerated, and no patient interrupted the prophylaxis.

Increased postoperative bleeding may be another short-term side effect of indomethacin.^{7,8} The antithrombotic effect of anti-inflammatory drugs combined with low-dose heparin has not been shown to increase postoperative bleeding in clinical trials.^{20,21}

In a recent report, the combination of indomethacin and warfarin caused no significant differences in the average maximum prothrombin time or bleeding complications in THA when compared with a matched-pair control group with warfarin only.³⁹ Although we did not observe any severe increase in postoperative bleeding, this possible side effect was not especially evaluated in this study.

Inhibition of bony ingrowth for uncemented THA and nonunion of trochanter osteotomy are long-term side effects of indomethacin prophylaxis.⁴⁰ Inhibition of new bone formation has been shown to be dose-dependent.²⁸

In our trial, using 50 mg indomethacin twice daily for 14 days, no clinical or radiographic signs of aseptic loosening after primary uncemented THA were found with a minimum of 24 months of follow-up. This finding is supported by our clinical experience in more than 2500 cases of uncemented THA in which this standard protocol was routinely used. Nevertheless, the clinical significance of bony ingrowth inhibition by indomethacin in cementless THA can only be determined by a randomized, placebo controlled study with long-term follow-up.

CONCLUSION

Short-term indomethacin prophylaxis is an effective, inexpensive, and easily administered therapy to prevent heterotopic ossification. Based on our experience with anti-inflammatory prophylaxis since 1987, general short-term

indomethacin heterotopic ossification prophylaxis combined with gastric protection is a sufficient and safe method for nearly all patients undergoing THA.

REFERENCES

1. Arcq M. Die paraartikulären Ossifikationen—eine Komplikation der Totalendoprothese der Hüfte. *Archiv für Orthopädie und Unfallchirurgie*. 1973; 77:108-131.
2. Ritter MA, Vaughan RB. Ectopic ossification after total hip arthroplasty. *J Bone Joint Surg Am*. 1977; 59:345-351.
3. Morrey BF, Adams RA, Cabanela ME. Comparison of heterotopic bone after anterolateral, transtrochanteric, and posterior approaches for total hip arthroplasty. *Clin Orthop*. 1984; 188:160-167.
4. Brooker AF, Bowerman JW, Robinson RA, Riley LH Jr. Ectopic ossification following total hip replacement. Incidence and method of classification. *J Bone Joint Surg Am*. 1986; 55:1629-1632.
5. Goel A, Sharp DJ. Heterotopic bone formation after hip replacement. *J Bone Joint Surg Br*. 1991; 73:255-257.
6. Kjaesgaard-Andersen P, Schmidt St A. The role of antiinflammatory medications in the prevention of heterotopic ossification. *Clin Orthop*. 1991; 263:78-86.
7. Kjaesgaard-Andersen P, Ritter MA. Current concepts review. prevention of formation of heterotopic bone after total hip arthroplasty. *J Bone Joint Surg Am*. 1991; 73:942-947.
8. Naraghi FF, DeCoster TA, Moneim MS, Miller RA, Rivero D. Heterotopic ossification: review. *Orthopaedics International Edition*. 1996; 4:131-141.
9. Riska EB, Michelson J-E. Treatment of para-articular ossification after total hip replacement by excision and use of free fat transplants. *Acta Orthop Scand*. 1979; 50:751-754.
10. Abrahamson S-O, Ahigren A-A, Dahlström JA, Ohlin P, Stigson L. Ectopic bone after hip replacement. *Acta Orthop Scand*. 1984; 55:589-592.
11. Ayers DC, Evarts McC, Parkinson JR. The prevention of heterotopic ossification in high-risk patients by low-dose radiation therapy after total hip arthroplasty. *J Bone Joint Surg Am*. 1986; 68:1423-1430.
12. Healy WL, Lo TC, Covall DJ, Pfeiffer BA, Wasilewski St A. Single-dose radiation therapy for prevention of heterotopic ossification after total hip arthroplasty. *J Arthroplasty*. 1990; 5:369-375.
13. Eyb R, Knahr K. The effect of prophylaxis for thrombosis on heterotopic ossification following total hip joint replacement. *Arch Orthop Trauma Surg*. 1983; 102:114-117.
14. Schmidt St A, Kjaesgaard-Andersen P, Pedersen NW, Kristensen S, Pedersen P, Nielsen JB. The use of indomethacin to prevent the formation of heterotopic bone after total hip replacement. *J Bone Joint Surg Am*. 1988; 70:834-838.
15. Freiberg A, Cantor R, Freiberg RA. The use of aspirin to prevent heterotopic ossification after total hip arthroplasty. *Clin Orthop*. 1991; 267:93-96.
16. Ahrengart L. Periarticular heterotopic ossification after total hip arthroplasty. *Clin Orthop*. 1991; 263:50-58.
17. Gebuhr P, Wilbek H, Soelberg M. Naproxen for 8 days can prevent heterotopic ossification after hip arthroplasty. *Clin Orthop*. 1995; 314:166-169.
18. Ritter MA, Sieber JM. Prophylactic indomethacin for prevention of heterotopic bone formation following total hip arthroplasty. *Clin Orthop*. 1985; 196:217-225.
19. Nilsson OS, Bauer HC, Brosjö O, Törnkvist H. Influence of indomethacin on induced heterotopic bone formation in rats. *Clin Orthop*. 1986; 207:239-245.
20. Knahr K, Salzer M, Eyb R, Frank P, Blauensteiner W. Heterotopic ossification with total hip endoprosthesis in various models of thrombosis prophylaxis. *Arthroplasty*. 1988; 3:1-8.
21. Kristensen S, Pedersen P, Pedersen NW, Schmidt St A, Kjaesgaard-Andersen P. Combined treatment with indomethacin and low-dose heparin after THR. *J Bone Joint Surg Br*. 1990; 72:447-449.
22. Kjaesgaard-Andersen P, Ritter MA. Short-term treatment with nonsteroidal antiinflammatory medications to prevent heterotopic bone formation after total hip arthroplasty. *Clin Orthop*. 1992; 279:157-162.
23. Wurnig Ch, Eyb R, Auersperg V. Indomethacin prevention of ectopic ossification in cementless hip arthroplasty. *Acta Orthop Scand*. 1992; 63:628-630.
24. McMahon JS, Waddell JP, Morton J. Effect of short-course indomethacin on heterotopic bone formation after uncemented total hip arthroplasty. *Arthroplasty*. 1991; 6:259-264.
25. Metzneroth H, Publig W, Knahr K, Zandl Ch, Kuchner G, Carda Ch. Osifikationsprophylaxe nach Hüfttotalendoprothesen mit Indomethacin und ihr Einfluß auf die Magenschleimhaut. *Z Orthop*. 1991; 129:178-182.
26. Ijiri K, Matsunaga S, Fukuda T, Shimizu T. Indomethacin inhibition of ossification induced by direct current stimulation. *Journal of Orthopaedic Research*. 1995; 13:123-131.
27. Wurnig Ch, Auersperg V, Böhler N, et al. Short term prophylaxis against heterotopic bone after cementless hip replacement. *Clin Orthop*. 1997; 334:175-183.
28. Trancik T, Mills W, Vinson N. The effect of indomethacin, aspirin, and ibuprofen on bone ingrowth into a porous-coated implant. *Clin Orthop*. 1989; 249:113-121.
29. Coventry MB, Scanlon PW. The use of radiation to discourage ectopic bone. *J Bone Joint Surg Am*. 1981; 63:201-208.
30. Lo TCM, Healy WL, Covall DJ, et al. Heterotopic bone formation after hip surgery: prevention with single-dose postoperative hip irradiation. *Radiology*. 1988; 168:851-854.
31. Sumner DR, Tumer TM, Pierson RH, et al. Effects of radiation on fixation of non-cemented porous-coated implant in a canine model. *J Bone Joint Surg Am*. 1990; 72:1527-1533.
32. Wise MW III, Robertson ID, Lachiewicz PF, Thrall DE, Metcalf M. The effect of radiation therapy on the fixation strength of an experimen-

tal porous-coated implant in dogs. *Clin Orthop.* 1990; 261:276-280.

33. Pellegrini VD Jr, Konski A, Gastel JA, Rubin P, Evarts CM. Prevention of heterotopic ossification with irradiation after total hip arthroplasty. *J Bone Joint Surg Am.* 1992; 74:186-200.

34. Pagnani MJ, Pellicci PM, Salvati EA. Effect of aspirin on heterotopic ossification after total hip arthroplasty in men who have osteoarthritis. *J Bone Joint Surg Am.* 1991; 73:924-929.

35. Kjaesgaard-Andersen P, Nafei A, Teichert G, et al. Indomethacin for prevention of hetero-

topic ossification. *Acta Orthop Scand.* 1993; 64:636-642.

36. Ahrengart L, Blomgren G, Törnkqvist H. Short-term ibuprofen to prevent ossification after hip arthroplasty. *Acta Orthop Scand.* 1994; 65:139-141.

37. Dorn U, Grethen C, Effenberger H, Berka H, Ramsauer H, Drekonja T. Indomethacin for prevention of heterotopic ossification after hip arthroplasty: a randomized comparison between 4 and 8 days of treatment *Acta Orthop Scand.* 1998; 69:107-110.

38. Ayers DC, Pellegrini VD, Evarts MC. Prevention of heterotopic ossification in high-

risk patients by radiation therapy. *Clin Orthop.* 1991; 263:87-93.

39. Fowble VA, Amstutz HC, Dorey FJ, Schmalzried TP. Effect of indomethacin on low-dose warfarin thromboembolic prophylaxis following total hip arthroplasty. Presented at the 63rd Annual Meeting of the American Academy of Orthopaedic Surgeons; February 22-27, 1996; Atlanta, Ga.

40. Jacobsson A-A, Djerf K, Ivarsson I, Wahlstrom O. Effect of diclofenac on fixation of hydroxyapatite-coated implant. *J Bone Joint Surg Br.* 1994; 76:831-833.