

## Modified Austin Procedure for Correction of Hallux Valgus

Hans-Jörg Trnka, M.D.,\* Alexander Zembsch, M.D.,\* Hermann Wiesauer, M.D.,\* Marc Hungerford, M.D.,†  
Martin Salzer, M.D.,‡ and Peter Ritschl, M.D.\*  
Vienna, Austria, and Baltimore, Maryland

### ABSTRACT

The Austin osteotomy is a widely accepted method for correction of mild and moderate hallux valgus. In view of publications by Kitaoka et al. in 1991 and by Mann and colleagues, a more radical lateral soft tissue procedure was added to the originally described procedure. From September 1992 to January 1994, 85 patients underwent an Austin osteotomy combined with a lateral soft tissue procedure to correct their hallux valgus deformities. Seventy-nine patients (94 feet) were available for follow-up.

The average patient age at the time of the operation was 47.1 years, and the average follow-up was 16.2 months. The average preoperative intermetatarsal angle was 13.9°, and the average hallux valgus angle was 29.7°. After surgery, the feet were corrected to an average intermetatarsal angle of 5.8° and an average hallux valgus angle of 11.9°. Sesamoid position was corrected from 2.1 before surgery to 0.5 after surgery. The results were also graded according to the Hallux Metatarsophalangeal Interphalangeal Score, and the functional and cosmetic outcomes were graded by the patient. Dissection of the plantar transverse ligament and release of the lateral capsule repositioned the tibial sesamoid and restored the biomechanics around the first metatarsophalangeal joint. There was no increased incidence of avascular necrosis of the first metatarsal head compared with the original technique.

### INTRODUCTION

A widely accepted method for correction of mild and moderate hallux valgus is the Austin or chevron osteotomy, a distal metatarsal osteotomy.<sup>2,14,20</sup> As this procedure gained popularity, various modifications were advocated.<sup>4,22</sup> Kitaoka et al.<sup>13</sup> concluded that lateral capsulotomy in combination with bunionectomy and medial capsulorrhaphy decreased the

incidence of radiographic recurrence and reoperations. Mann and Coughlin<sup>16</sup> stated that if the sesamoids are not repositioned adequately, the incidence of early recurrence may increase.

The Austin osteotomy is usually limited to patients who have congruent metatarsophalangeal (MTP) joints, an intermetatarsal (IM) angle less than 15°, and a hallux valgus (HV) angle less than 35° without pronation of the toe.<sup>14</sup>

After reviewing our patients who underwent surgery according to the originally described Austin technique, we were not absolutely satisfied with the results of sesamoid repositioning or HV and IM angle correction, but we also realized that we had stretched the indication for this procedure by using it also in cases of incongruent MTP joint. In September 1991, we started to combine the original Austin technique with a lateral soft tissue release through a separate incision.

The purpose of this study was to present our early clinical and radiological results with this modified technique, with respect to maintenance of correction and subjective and objective evaluation of outcome, and to state whether this combined technique is able to achieve better correction of the deformity than the original Austin technique.

### PATIENTS AND METHODS

Eighty-four patients with 100 bunions (16 bilateral) underwent surgical correction for mild and moderate hallux valgus deformities with a combination of a distal chevron first metatarsal osteotomy and a lateral soft tissue release performed by various surgeons, including residents, between September 1992 and January 1994. Seventy-six patients (90 operated feet) were women, and 8 patients (10 feet) were men. The average age was 47.1 years (range, 17–77 years). Clinical indications for surgery included pain over the bunion, difficulty with shoe fit, and significant foot deformity. Radiological criteria included IM angle of 10° or greater, HV angle greater than 20°, and lateral subluxation of the sesamoids. Joint congruence did not af-

\* I. Department Orthopaedic Hospital Gersthof, Wilemansgasse 28, 1180 Vienna, Austria. Address requests for reprints to Dr. Hans-Jörg Trnka.

† Johns Hopkins University, Baltimore, MD 21202.

‡ Herz Jesu Hospital, Vienna, Austria.

fect our decision. There were no exclusion criteria for this study.

### Radiological Assessment

Before surgery and at the time of the final follow-up, dorsoplantar and lateral weightbearing and non-weightbearing radiographs were obtained.<sup>11,26</sup> At that time, weightbearing and nonweightbearing radiographs were obtained because we thought that we might get more information about the splay foot. This practice has been discontinued. The HV angle, the first IM angle, the congruence of the first MTP joint, and the metatarsal index were measured by the methods recommended by the American Orthopaedic Foot and Ankle Society.<sup>27</sup> The sesamoid position was evaluated by measuring the position of the medial sesamoid relative to a longitudinal line bisecting the first metatarsal shaft (reference line) and was classified in the following manner: grade 0, no displacement of sesamoid relative to the reference line; grade I, overlap of less than 50% of sesamoid relative to the reference line; grade II, overlap of greater than 50% of sesamoid relative to the reference line; and grade III, sesamoid completely displaced beyond the reference line. Furthermore, radiographs were graded according to Mann (grade I, HV  $\leq$  15, IM  $\leq$  10; grade II, HV  $\leq$  30, IM  $\leq$  15; grade III, HV  $\leq$  40, IM  $\leq$  20; and grade IV, HV  $>$  40, IM  $>$  20). Grades I and II were considered as moderate and grade III and IV as severe hallux valgus deformity.<sup>18</sup> The criteria for the radiological diagnosis of AVN were defined by Meier and Kenzora.<sup>19</sup>

### Clinical Assessment

At the time of the final follow-up, patients were interviewed and graded by a standardized score<sup>28</sup> based on the Hallux Metatarsophalangeal Interphalangeal Scale (HMIS) of the American Orthopaedic Foot and Ankle Society.<sup>13</sup> This score of 100 points includes the clinical parameters of pain (40 points), activity limitations (10 points), footwear requirements (10 points), MTP joint motion (10 points), interphalangeal (IP) joint motion (5 points), MTP-IP stability (5 points), callus related to hallux MTP-IP (5 points), and alignment (15 points). The result was rated excellent if it was between 100 and 93 points, good was between 92 and 83 points, fair was between 82 and 66 points, and poor was less than 65 points. We tried to assign a grade using the HMIS by analyzing the score and determining whether the score should be considered excellent, good, fair, or poor.

Additionally, patients were asked to rate their feet for overall satisfaction and cosmesis. The cosmetic result was graded excellent if the great toe was clini-

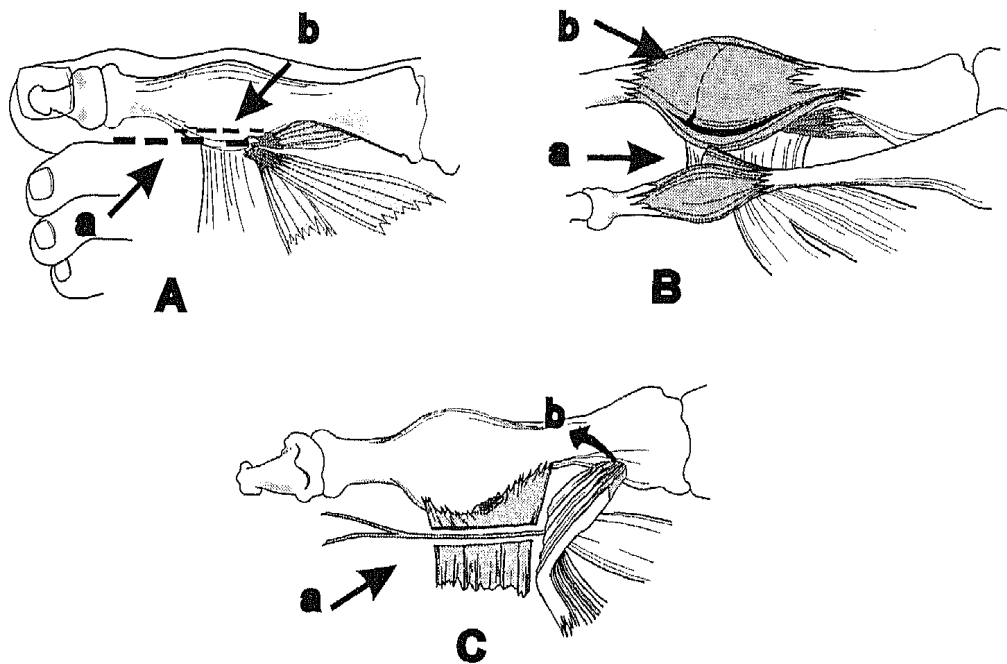
cally in a straight position without any excessive scar formation. Furthermore, the range of motion of the MTP joint was measured. The range of plantarflexion and dorsiflexion, measured from the floor, was graded from excellent to poor. Plantarflexion of more than 30° was graded as excellent, from 20° to 30° as good, from 10° to 20° as fair, and less than 10° as poor. Dorsiflexion of more than 60° was graded excellent, from 45° to 60° as good, and from 30° to 45° as fair, and less than 30° as poor. In addition, patients were asked if they used a shoe insert or arch support.

### Surgical Technique

All procedures were performed under peripheral nerve block and Esmarch tourniquet. First, an incision was made on the dorsal aspect of the foot in the first IM space. A longitudinal incision was then made in the lateral joint capsule just superior to the lateral sesamoid (Fig. 1A). The adductor tendon was identified and carefully dissected from the lateral capsule and then released from its insertion into the base of the proximal phalanx. The lateral capsule was perforated at the joint line and the toe was forced manually into 20° varus position (Fig. 1B). The transverse metatarsal ligament was stretched and carefully incised to release the tethering effect on the sesamoid complex. Sutures were placed through the adductor tendon and into the lateral aspect of the first metatarsal to lift the insertion of the adductor muscle using two stabilizing sutures (Fig. 1C).

A medial skin incision was made over the first MTP joint from midshaft of the proximal phalanx to approximately midshaft of the metatarsal. An inverted L or lenticular medial capsulotomy was utilized to expose the medial eminence. The medial eminence was excised using an osteotome or power saw. The excision of the medial eminence began 1 mm medial to the sagittal sulcus and was performed in line with the medial aspect of the metatarsal shaft (Fig. 2A).

A K-wire was drilled exactly transverse through the first metatarsal head, aiming at the head of the third or fourth metatarsal, depending on whether the first metatarsal needed to be lengthened. Two cuts were then made with an oscillating power saw to form an angle of 60° with the apex at the drill hole, taking care that each cut was made precisely to ensure stability, which is the essence of the procedure (Fig. 2B). Once the capital fragment was freely mobile, it was transposed laterally 3 mm to 6 mm (Fig. 2C). When the joint surfaces were in correct alignment and the metatarsal head was in place, the capital fragment was firmly impacted on to the metatarsal shaft, and the resulting medial step defect was removed (Fig. 2D). Unless



**Fig. 1.** A, First, an incision is made in the first intermetatarsal space (a). A longitudinal incision is made in the lateral joint capsule (b). B, The adductor tendon is dissected from the lateral capsule (a). The lateral capsule is perforated at the joint line (b). C, The transverse metatarsal ligament is stretched and incised (a). Sutures are placed through the adductor tendon and the lateral aspect of the first metatarsal, and two stabilizing sutures are placed (b).

instability of the metatarsal head was evident, no internal fixation was required. A pressure dressing was used to secure the hallux and control postoperative bleeding and edema.

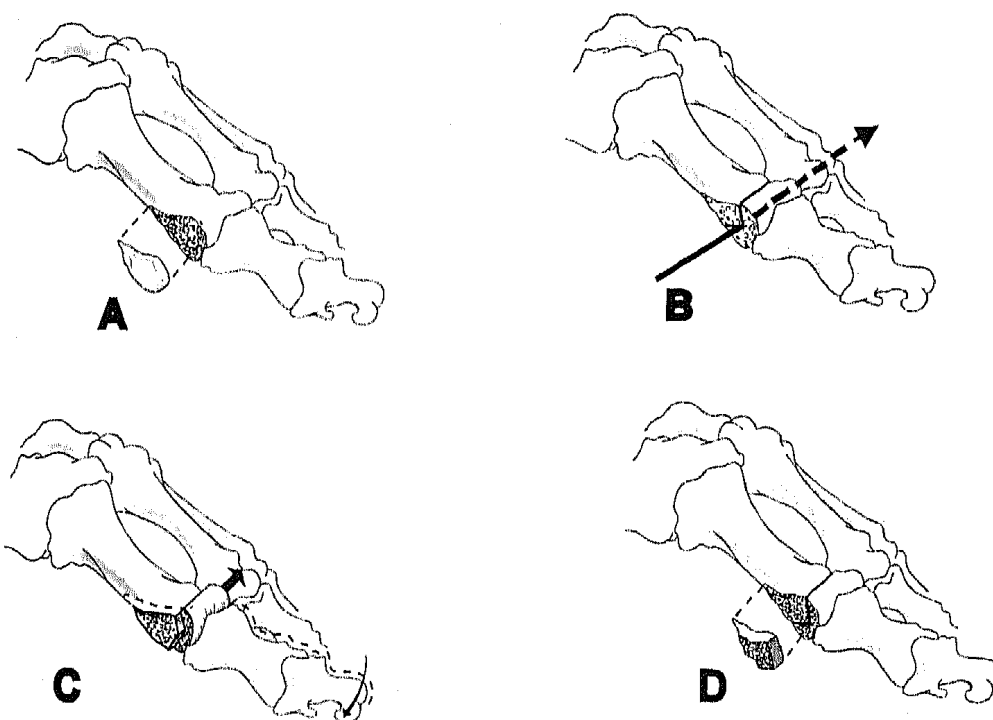
The first dressing change took place on the second day after surgery. For the first 5 days, each patient was not allowed to bear weight and used a wheelchair. At 5 days after surgery, dorsoplantar and lateral x-rays were obtained. If any evidence of instability was noted, patients were placed in a short leg walking cast; otherwise a bunion shoe with a wooden sole was fitted. The great toe was kept in the proper position with cloth tape, and the dressing was changed once a

week for 6 weeks. Three months after the operation, patients were fitted with custom-made arch supports.

### RESULTS

Seventy-nine patients (94 feet) were followed for an average of 16.2 months (range, 12–32 months). Two patients were lost to follow-up, and four refused the follow-up examination.

By HMIS evaluation, 87% of the feet were rated excellent or good, 10% fair, and 3% poor. The average postoperative HMIS score was 91.6 points. Patients subjectively rated the outcome of the operation



**Fig. 2.** A, Medial eminence removal. B, Guidewire, aiming at the third or fourth metatarsal head and V-shaped osteotomy through the first metatarsal head. C, Lateral displacement of the first metatarsal head. D, Removal of the resulting protuberance.

**TABLE 1**  
Clinical Results of All Patients

Grade <sup>a</sup>	Clinical results <sup>b</sup>				
	HMIS	PS	C	Plantar	Dorsal
Excellent	61	82	83	12	7
Good	26	13	15	34	28
Fair	10	2	2	28	55
Poor	3	5	0	26	10

<sup>a</sup> Grade in percent.

<sup>b</sup> HMIS, Hallux Metatarsophalangeal Interphalangeal Scale (Ref. 13); PS, patient satisfaction; C, cosmesis; Plantar, plantarflexion; Dorsal, dorsiflexion.

as excellent (80%), good (13%), fair (2%), and poor (5%).

The cosmetic results were rated excellent in 83%, good in 15%, and fair in 2%. No foot was rated a cosmetically poor result by any patient (Table 1).

At follow-up, the average angle of dorsiflexion was 20.3°, and the average angle of plantarflexion was 42.4°. According to our very conservative rating system, plantarflexion was graded as excellent in 12%, good in 34%, fair in 28%, and poor in 26%. Dorsiflexion was graded as excellent in 7%, good in 28%, fair in 55%, and poor in 10%. Regarding the use of the recommended arch support or shoe insert, 55% of the patients were wearing arch supports at the time of follow-up.

Preoperative roentgenographs were available in 84 cases and at the time of the long-term follow-up in 97 cases. In 70 cases, pre- and postoperative radiographs were available. The radiographic results (Table

**TABLE 2**  
Radiological Results of All Patients

	Radiological results <sup>a</sup>			
	HV <sup>b</sup>	IM <sup>b</sup>	SP <sup>b</sup>	JC <sup>c</sup>
Preop	29.7 ± 8.1	13.9 ± 3.9	2.1 ± 0.8	59
Postop	11.9 ± 9.1	5.8 ± 3.4	0.5 ± 0.9	92

<sup>a</sup> HV, hallux valgus angle; IM, intermetatarsal angle; SP, sesamoid position; JC, joint congruency; Pre-op, before surgery; Post-op, after surgery.

<sup>b</sup> Mean ± standard deviation.

<sup>c</sup> Joint congruency in percent.

**TABLE 3**  
Radiological Results: Austin Versus Combined Technique<sup>a</sup>

	HV <sup>b</sup>	HV <sup>b</sup>	IM <sup>b</sup>	IM <sup>b</sup>	SP <sup>b</sup>	SP <sup>b</sup>	JC <sup>c</sup>	JC <sup>c</sup>
	preop.	postop.	preop.	postop.	preop.	postop.	preop.	postop.
Austin	30.0°	17.8°	13.7°	8.1°	1.8	0.8	50%	80%
Modified	29.7°	11.9°	13.9°	5.8°	2.1	0.6	59%	92%

<sup>a</sup> HV, hallux valgus angle; IM, intermetatarsal angle; SP, sesamoid position; JC, joint congruency; Pre-op, before surgery; Post-op, after surgery.

<sup>b</sup> Mean.

<sup>c</sup> Joint congruency in percent.

2) revealed an average preoperative MTP angle of 29.7° (standard deviation [SD], 7.6; range, 14° to 50°). After surgery, the average angle was 11.9° (SD, 6.9; range, 0° to 28°), for a correction of 17.6°. The average first IM angle was 13.9° (SD, 2.7; range, 7° to 19°) before surgery and 5.8° (SD, 2.7; range, 0° to 12°) after surgery, for an average correction of 8.1°.

The sesamoid position was corrected from an average grade of 2.1 before surgery to 0.6 after surgery. Before surgery, no patient had sesamoid position of grade 0, 22% had grade I, 42% had grade II, and 36% had grade III. After surgery, 53% of the patients had sesamoid position of grade 0, 43% had grade I, 4% had grade II, and no cases of grade III were seen.

Before surgery, the first MTP joint was congruent in 42 of the 84 available radiographs. After surgery, the first MTP was rated congruent in 91 of the available 97 radiographs. Where the first MTP joint was incongruent before surgery, it was not corrected after surgery in only 4 of 42 (9.5%) patients. If the first MTP joint was congruent before surgery in 11 of 39 (28%) cases, for which pre- and postoperative radiographs were available, the HV angle was greater than 15° (average, 12.1°). In cases of preoperative joint incongruity, in 11 of 31 (35%) cases, the HV angle was greater than 15° (average, 11.7°).

Before surgery, 37% of patients had Mann deformity grade II, 52% grade III, and 11% grade IV. No patient had grade I deformity. After surgery, this improved to 69% grade I and 31% grade II. No case after surgery had grade III or grade IV deformity.

We compared our results with a series of patients who underwent surgery earlier according to the Austin technique without separate incision<sup>27</sup> (Table 3). With the Austin technique without separate incision, the average preoperative MTP angle of 30.0° was corrected to 17.8° and the average first IM angle from 13.7° before surgery to 8.1° after surgery. The sesamoid position was corrected from an average grade of 1.8 before surgery to 0.8 after surgery.

Before surgery, 50% of the first MTP joints were congruent; this improved to 80% with the operation. In 9 of 25 (36%) patients where the first MTP joint was

**TABLE 4**  
**Radiological Results for Patients <50 Years Versus >49**  
**Years and Preoperatively Incongruent First MTP Joint Versus**  
**Congruent First MTP Joint**

	Mean angles <sup>a</sup>					
	HV preop.	HV postop.	IM preop.	IM postop.	SP preop.	SP postop.
<50	28.9°	11.4°	13.6°	5.9°	1.9	0.5
>49	30.1°	13.5°	14.1°	5.8°	2.3	0.7
Incongruent	33.7°	11.3°	15.0°	5.3°	2.5	0.6
Congruent	25.9°	12.8°	12.9°	5.9°	1.7	0.6

<sup>a</sup> HV, hallux valgus angle; IM, intermetatarsal angle; SP, sesamoid position; preop., before surgery; postop., after surgery.

incongruent before surgery, the joint incongruity could not be corrected. If the first MTP joint was congruent before surgery in 12 of 25 (48%) cases, where pre- and postoperative radiographs were available, the HV angle was greater than 15° (average, 12.1°). In cases of preoperative joint incongruity, in 14 of 25 (56%) cases, the HV angle was greater than 15° (average, 11.7°).

Using the deformity classification of Mann, no patients were preoperative grade I, 50% were grade II, 32% grade III, and 8% grade IV. After surgery, grade I was assigned to 44%, grade II to 50%, grade III to 4%, and grade IV to 2%.

Because of instability of the metatarsal head, one osteotomy required fixation with a K-wire, and three patients wore walking casts for 4 weeks instead of postoperative shoes. In three patients, as far as it was possible to determine, a minimal change of the position of the osteotomy occurred between the immediate postoperative period and the long-term follow-up. Two of these patients presented with a plantar tilt and one with a lateral tilt.

Comparison of the clinical results of groups of patients younger (49 patients) and older (51 patients) than age 50 years revealed that the older group achieved better results regarding subjective patient satisfaction (patients < 50 years, 88.9% excellent or good; patients > 49 years, 95.8% excellent or good), but the more objective HMIS revealed a higher average score for the younger group (92.5 points versus 90.5 points).

Analysis of the radiological results revealed an average HV angle of 11.4°, average IM angle of 5.9°, and an average sesamoid position of 0.5 in the younger group versus an average HV angle of 13.5°, average IM angle of 5.8°, and an average sesamoid position of 0.7 in the older group (Table 4).

An analysis of first MTP joints that were incongruent before surgery may influence the outcome of the procedure as performed. Of patients who had an incon-

gruent first MTP joint before surgery, 92.5% rated the clinical outcome as excellent or good, whereas 94.8% of patients with a congruent first MTP joint before surgery rated their results as excellent or good. The average HMIS was 90.2 points versus 93.2 points. Comparison of the radiological results of the two groups revealed that the correction was similar (Table 4).

Associated procedures included single telescoping osteotomy (Helal) of the metatarsal neck of metatarsals II to IV (4 feet), resection of the first phalangeal head for hammertoe deformity (18 feet), and distal metatarsal osteotomy of the fifth metatarsal for bunionette (1 foot). In one case, an extensor tendon lengthening, osteotomy of the second metatarsal neck, and capsulotomy of the MTP joint for a cross-over second toe were performed.

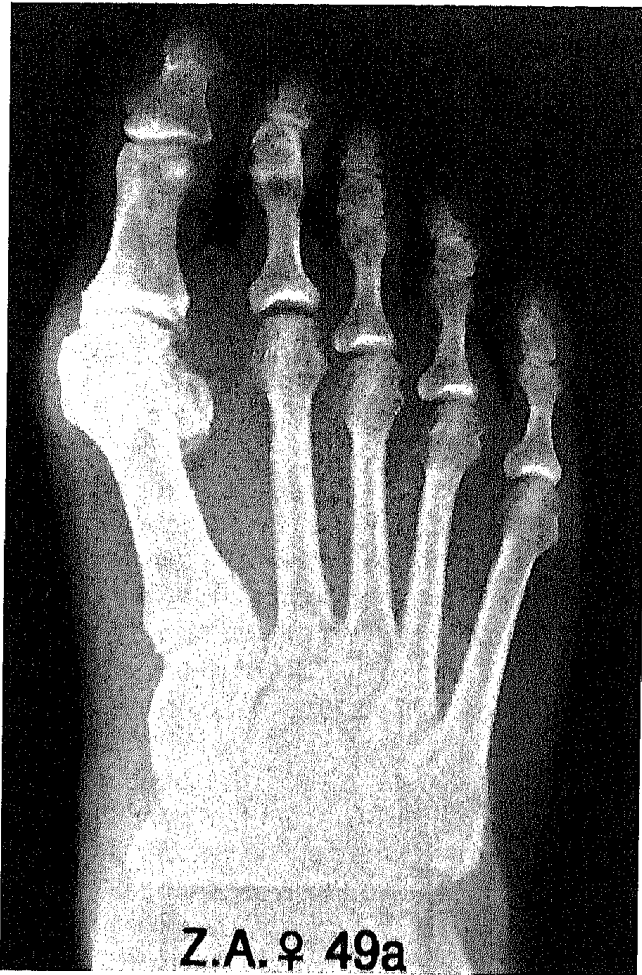Analyzing the complications, we found eight cases of hallux varus deformities, six of which were mild (1° to 10°). Four cases of superficial wound infections and four cases of hypesthesias of the first dorsal nerve were observed. Three patients developed reflex sympathetic dystrophy (RSD), with the symptoms of diffuse pain, swelling, reddish coloration, and trophic changes, which resolved with physiotherapy.

One patient had to undergo revision surgery because of dislocation of the head fragment. Avascular necrosis (AVN) of the first metatarsal head was seen in three cases, one of which was symptomatic.

## DISCUSSION

Bunionectomy with a distal V-shaped osteotomy, also called Austin or chevron osteotomy, has gained in popularity in the last 10 years. The reason for this popularity is its ease and reliability. Early reports by Austin and Leventen,<sup>2</sup> Leventen,<sup>14</sup> Corless,<sup>3</sup> and Johnson et al.<sup>9</sup> suggested a high rate of satisfaction. With more experience, the limits and complications of this technique have become evident.

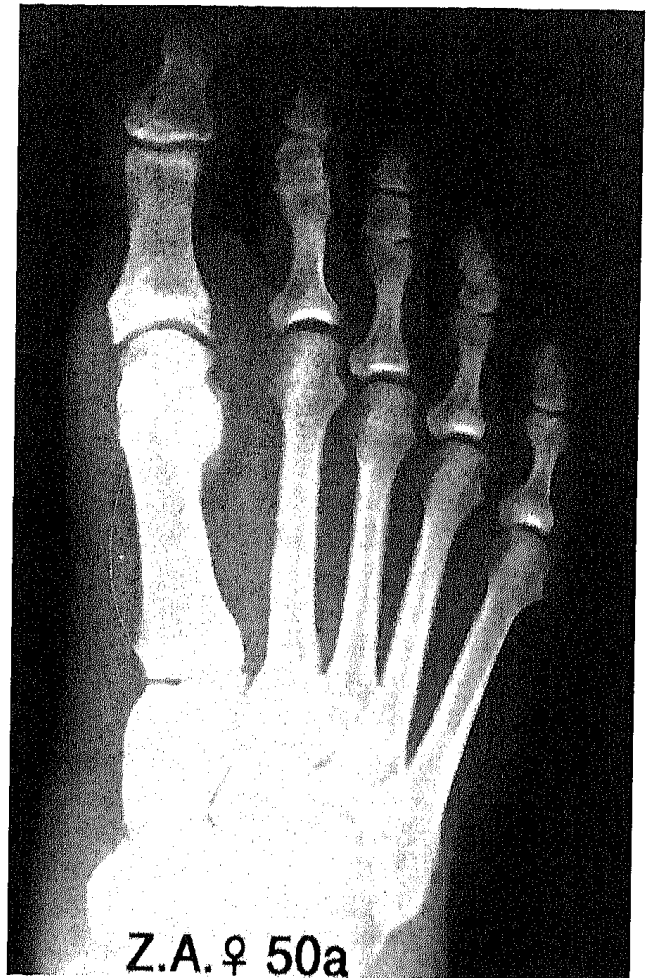After analyzing the results obtained using the original technique, we looked for some modifications to increase the effectiveness of this procedure. Kitaoka et al.<sup>12</sup> reported the addition of lateral capsulotomy to a simple bunionectomy. This decreased the incidence of recurrence. Payr,<sup>21</sup> in 1925, Mann and Pfeffenger,<sup>17</sup> and Mann et al.<sup>18</sup> stated that while the hallux valgus deformity progresses and the proximal phalanx moves laterally on the metatarsal head, there will be attenuation of the medial joint capsule as well as a progressive contracture of the lateral joint capsule. Hohmann<sup>6</sup> pointed out the importance of restoring the normal biomechanics of the muscles around the first MTP joint, and Payr<sup>21</sup> tried to achieve this by simple bun-



**Fig. 3.** Preoperative roentgenogram of 49-year-old woman, showing an angle of  $27^\circ$  between the phalanx and the metatarsal bone of the great toe and an angle of  $18^\circ$  between the first and second metatarsals.

ionectomy and lateral capsulotomy. In a cadaver study, Appel and Grading<sup>1</sup> examined the morphological features of the adductor hallucis muscle and advised the detachment of the adductor tendon from its insertion. Mann and Pfeffenger<sup>17</sup> and Mann et al.<sup>18</sup> recommended a lateral soft tissue procedure with bunionectomy for mild hallux valgus deformities and a combination of soft tissue procedure and proximal crescentic osteotomy for more severe deformities. Influenced by these publications, we added to the original Austin technique the perforation of the lateral joint capsule, the dissection of the deep transverse ligament, and two stabilizing sutures through a second skin incision in the first web space.

Reestablishing the normal shape and function of the foot is the main goal of any hallux valgus procedure.<sup>6</sup> In this series, the HV and IM angles were corrected an average of  $18^\circ$  and  $8^\circ$ , respectively (Figs. 3 and 4). Twenty-three feet had a postoperative HV angle of greater than  $15^\circ$ , but 17 of these patients rated the outcome of the operation as excellent. This may be related to the fact that for the patient, the pain relief



**Fig. 4.** Same patient in Figure 3. Sixteen months after osteotomy, the HV angle was reduced to  $8^\circ$  and the IM angle was reduced to  $8^\circ$ .

was more important than the cosmetic appearance. The distal soft tissue procedure effectively repositioned the tibial sesamoid to an average of grade 0 in 53% and grade 1 in 43%, which could not be achieved (39% grade 0 and 41% grade 1) in our previous series without this additional procedure. Johnson et al.,<sup>9</sup> who used a classic chevron procedure without adductor release, described a sesamoid position correction from 1.4 before surgery to 1.0 after surgery. Leventen<sup>14</sup> improved the lateral sesamoid coverage from 33% to 41%. Rossi and Ferreira<sup>25</sup> corrected the sesamoid position from 39.9% grade 1 before surgery and no case of grade 0 to 44.4% grade 0 and 51.8% grade 1 after surgery. Resch et al.<sup>24</sup> and Johnson et al.<sup>8</sup> did not mention the sesamoid position.

The stabilizing interdigital sutures and the subsequent scar tissue may also help to keep the first metatarsal in its corrected position.

A major question is whether or not internal fixation should be placed. In this series, internal fixation was usually not performed. In one case, a wire fixation and in three cases a walking cast for 4 weeks was used because of instability of the osteotomy which was observed intraoperatively. In three cases, the metatar-

sal osteotomies changed positions between the period immediately after surgery and long-term follow-up. Currently, we routinely place a temporary K-wire for 6 weeks.

According to Leventen,<sup>14</sup> there is no indication for the original Austin procedure in cases of incongruent first MTP joint., whereas Johnson et al.<sup>9</sup> stated that in the ideal candidate for a chevron osteotomy, the MTP joint will be subluxed. In our first series, using the Austin procedure without separate skin incision, a 56% recurrence rate of a HV angle of greater than 15° was seen in cases with an incongruent joint before surgery versus a 48% incidence in cases with a congruent joint. Using the modified technique, there was 35% and 28% recurrence, respectively. With the separate skin incision, the incidence of recurrence of HV angle of greater than 15° in cases of preoperatively incongruent first MTP joint was less than in cases of congruent first MTP joint using the Austin procedure. Also, the analysis of the clinical results reveals no significant difference whether the first MTP joint was incongruent or congruent before the surgery. The radiological results show that in the presence of a preoperatively incongruent first MTP joint there was preoperatively more deformity but the radiological results were similar to the cases with preoperatively congruent first MTP joint. We therefore agree that a traditional Austin or chevron procedure should not be performed in case of an incongruent first MTP joint. However, in case of an incongruent joint, with the separate skin incision, dissection of the transverse MTP ligament, and release of the lateral joint capsule and the adductor tendon, a high incidence of recurrence of a HV angle of more than 15° can be avoided and sufficient correction of the deformity can be achieved.

Johnson et al.<sup>8</sup> and Resch et al.<sup>24</sup> stated that the additional adductor tenotomy did not improve the correction of the HV angle and the first IM angle of a chevron osteotomy. Both performed the adductor tenotomy through the joint, but Resch did not release the lateral capsule. We performed the adductor tenotomy in all of our series.<sup>28</sup> Judging from the results of the modified technique, the adductor tenotomy alone is not enough. The addition of the dissection of plantar transverse ligament and the release of the lateral capsule allows the sesamoids to migrate medially and to transpose the head fragment laterally. Comparing the results of this series with a series in which the operation was done according to the original Austin technique,<sup>28</sup> a much better correction of the HV angle, IM angle, and most importantly sesamoid position was observed. If we compare the results of the Mann classification, it is evident that the correction can be improved using the modified technique. After using the

modified technique, 69% of the cases were grade I; with the original technique, 44% were grade I. There were no cases of grade III and grade IV with the modified technique but 4% grade III and 2% grade IV using the original technique.

While lateral soft tissue release is a conceptually appealing addition to the Austin osteotomy, many authors have raised the specter of first metatarsal AVN in cautioning against the procedure.<sup>7,15,19,25</sup> Jahss,<sup>7</sup> Mann,<sup>15</sup> and Meier and Kenzora<sup>19</sup> have all suggested that AVN frequently accompanies lateral release performed in addition to chevron osteotomy, citing an incidence of up to 40%.<sup>19</sup> However, analyzing the article by Meier and Kenzora,<sup>19</sup> we found out that of a group of 138 patients treated with distal metatarsal osteotomies, 50 were available for follow-up. A chevron osteotomy was performed in 41 patients (60 feet). Of these 60 feet, an adductor tenotomy was added in only 10 cases, and 4 of these patients developed AVN. Therefore, the authors should have stated that there was a complication in 4 of 10 patients, which may be related to a learning curve, instead of stating that the incidence of AVN is 40% after a chevron osteotomy with an additional adductor tenotomy.

In contrast, Johnson et al.<sup>9</sup> reviewed 12 cases of chevron osteotomy combined with lateral soft tissue release through an transarticular adductor release and found no cystic changes or signs of AVN of the metatarsal head. Pochatko et al.<sup>22</sup> published a series of 23 of 42 patients who were operated on using the combined technique and found no evidence of AVN. Resch et al.<sup>23</sup> studied the circulatory disturbance of the metatarsal head using bone scintigraphy in a randomized study of a group of patients with chevron osteotomy versus a group of patients with chevron osteotomy and adductor tenotomy. They found no increased risk if the adductor tenotomy was added. Johnston Jones et al.<sup>10</sup> demonstrated in cadaver specimens that technical errors alone can result in damage to the vessels that supply the metatarsal head.

Our study showed evidence of AVN verified by magnetic resonance imaging (MRI) in three cases at a minimum of 12 months after surgery. In three other cases, in which AVN was suspected after reviewing standard radiographs, the MRI scans showed no evidence of AVN. All three confirmed cases of AVN occurred early in this series and probably resulted from overzealous soft tissue stripping or overpenetration of the saw blade,<sup>10</sup> although the exact cause is impossible to pinpoint.

A postoperative hallux varus deformity was observed in seven cases. As Mann et al.<sup>18</sup> stated, a mild degree of varus angulation did not seem to bother the patients. In all cases, too much bone on the medial

eminence was removed and the medial capsulorrhaphy was too tight. This highlights the importance of a limited medial osteotomy, appropriate soft tissue balance, and correct application of postoperative dressing.

Hattrup and Johnson<sup>5</sup> have noted that patients older than age 50 did less well with a distal chevron osteotomy. According to our results, there is no age limit for a distal Austin osteotomy with soft tissue release, as long as there is sufficient blood circulation in the forefoot and good bone quality. The skin incision over the first web space provides better visualization of the soft tissues and the vessels around the medial joint capsule and may also help to avoid interruption of the blood supply of the metatarsal head.

## CONCLUSIONS

Our results with regard to average first and second IM angle and HV angle correction, sesamoid position, and joint congruency revealed that excellent correction of the deformity had been achieved. In comparison to an earlier series with the original Austin technique, we achieved a much better correction of HV angle, IM angle, and most importantly of the sesamoid position, which we think plays an important role in the long-term correction of the hallux valgus deformity. In cases of incongruent first MTP joint before surgery, the combined procedure reveals an even lower incidence of a recurrence of HV angle of more than 15° than after the original Austin technique with a congruent joint before surgery. We relate these findings to the fact that if the contracture of the lateral soft tissue around the first MTP joint is released, the metatarsal head can be more easily repositioned over the sesamoids and the biomechanics around the first MTP joint will be restored. We recommend an Austin osteotomy with extensive lateral soft tissue release through a separate skin incision in patients with an IM angle of less than 16° and incongruent joints. The procedure is not limited to patients younger than age 50 years. In cases of an IM angle of less than 16°, a congruent first MTP joint, and a sesamoid position grade 0 and I, we recommend the chevron osteotomy without lateral soft tissue release. Nevertheless, only a randomized prospective investigation assessed by an independent observer will verify the advantage of the combined technique.

## REFERENCES

1. Appel, M., and Gradinger, R.: Die Morphologie des M. adductor hallucis und deren Bedeutung für die operative Behandlung des Hallux valgus. *Z. Orthop.*, **127**:326-330, 1989.
2. Austin, D.W., and Leventen, E.O.: A new osteotomy for hallux valgus: a horizontally directed "V" displacement osteotomy of the metatarsal head for hallux valgus and primus varus. *Clin. Orthop.*, **157**:25-30, 1981.
3. Corless, J.R.: A modification of the Mitchell procedure. *J. Bone Joint Surg.*, **58B**:138, 1976.
4. Donnelly, E.D., Saltzman, C.L., Kile, T.A., and Johnson, K.A.: Modified chevron osteotomy for hallux valgus. *Foot Ankle Int.*, **15**:642-645, 1994.
5. Hattrup, S.J., and Johnson, K.A.: Chevron osteotomy: analysis of factors in patient's dissatisfaction. *Foot Ankle*, **5**(6):327-332, 1985.
6. Hohmann, G.: *Fuß und Bein*. Fünfte Ausgabe. Munich, Verlag J.F. Bergmann, 1951, pp. 145-155.
7. Jahss, M.H.: Hallux valgus: further considerations—the first metatarsal head. *Foot Ankle*, **2**:1-4, 1981.
8. Johnson, J.E., Clanton, T.O., Baxter, D., and Gotlieb, M.S.: Comparison of chevron osteotomy and modified bunionectomy for correction of mild to moderate hallux valgus deformity. *Foot Ankle*, **12**(2):61-68, 1991.
9. Johnson, K.A., Cofield, R.H., and Morre, B.F.: Chevron osteotomy for hallux valgus. *Clin. Orthop.*, **142**:44-47, 1978.
10. Johnston Jones, K., Feiwell, L.A., Freedman, E.L., and Crachiolo, A.: The effect of chevron osteotomy with lateral capsular release on the blood supply to the first metatarsal head. *J. Bone Joint Surg.*, **77A**:197-203, 1995.
11. Karasick, D., and Wapner, K.L.: Hallux valgus deformity: preoperative radiologic assessment. *AJR Am. J. Roentgenol.*, **155**:119-123, 1990.
12. Kitaoka, H.B., Franco, M.G., Weaver, M.S., and Ilstrup, D.M.: Simple bunionectomy with medial capsulorrhaphy. *Foot Ankle*, **12**(2):86-91, 1991.
13. Kitaoka, H.B., Alexander, I.J., Adelaar, R.S., Nunley, J.A., Myerson, M.S., and Sanders, M.: Clinical rating systems for ankle-hindfoot, midfoot, hallux, and lesser toes. *Foot Ankle Int.*, **15**(7):349-353, 1994.
14. Leventen, E.O.: The chevron procedure. *Orthopedics*, **13**(9):973-976, 1990.
15. Mann, R.A.: Complications associated with the chevron osteotomy. *Foot Ankle*, **3**:125-129, 1982.
16. Mann, R.A., and Coughlin, M.: Adult hallux valgus. In Mann, R.(ed.), *Surgery of the Foot*, 5th ed. St. Louis, C.V. Mosby, 1986, p. 279.
17. Mann, R.A., and Pfeffinger, L.: Hallux valgus repair: DuVries modified McBride procedure. *Clin. Orthop.*, **272**:213-218, 1991.
18. Mann, R.A., Rudical, S., and Grave, S.T.: Repair of hallux valgus with a distal soft-tissue procedure and proximal metatarsal osteotomy. *J. Bone Joint Surg.*, **74A**:124-129, 1992.
19. Meier, P.J., and Kenzora, J.E.: The risks and benefits of distal metatarsal osteotomies. *Foot Ankle*, **6**(1):7-17, 1985.
20. Miller, S., and Croce, W.A.: The Austin procedure for surgical correction of hallux abductor valgus deformity. *J. Am. Podiatr. Assoc.*, **69**(2):110-118, 1979.
21. Payr, E.: Zur Hallux-valgus Operation: Kapselbandexcision an der lateralen Seite des Gelenkes. *Zentralbl. Ges. Chir.*, No. 41, 1925.
22. Pochatko, D.J., Schlehr, F.J., Murphey, M.D., and Hamilton, J.J.: Distal chevron osteotomy with lateral release for treatment of hallux valgus deformity. *Foot Ankle Int.*, **15**(9):457-461, 1994.
23. Resch, S., Stenström, A., and Gustafson, T.: Circulatory disturbance of the first metatarsal head after chevron osteotomy as shown by bone scintigraphy. *Foot Ankle*, **13**(3):137-142, 1992.
24. Resch, S., Stenström, A., Reynisson, K., and Jonsson, K.:



- Chevron osteotomy for hallux valgus not improves by additional adductor tenotomy. *Acta Orthop. Scand.*, **65(5)**:541-544, 1994.
25. **Rossi, W.R., Ferreira, J.C.A.:** Chevron osteotomy for hallux valgus. *Foot Ankle*, **13(7)**:378-381, 1992.
  26. **Scott, G., Wilson, D.W., and Bentley, G.:** Roentgenographic assessment in hallux valgus. *Clin. Orthop.*, **267**:143-147, 1991.
  27. **Smith, R.W., Reynolds, J.Ch., and Stewart, M.J.:** Hallux valgus assessment: report of research committee of American Orthopedic Foot and Ankle Society. *Foot Ankle*, **5(2)**:92-103, 1984.
  28. **Trnka, H.-J., Hofmann, S., Salzer, M., and Ritschl, P.:** Clinical and radiological results after Austin bunionectomy for treatment of hallux valgus. *Arch. Orthop. Trauma Surg.*, **115(3/4)**:171-175, 1996.